

Preface

Practice Patterns in Endophthalmitis

A Survey of Rajasthan Ophthalmological Society Members

Dr. Pavan Shorey

Hony. General Secretary

We conducted a survey of ROS members to assess the practice patterns they adopt while managing endophthalmitis. A questionnaire was sent to more than 100 ROS members in different parts of Rajasthan. 81 members of Jaipur, Jodhpur, Ajmer, Bikaner, Beawar, Sujangadh, Sri Ganganagar responded. Udaipur and Alwar ROS members did not respond. The results are as follows:

Endophthalmitis: Diagnosis and Management

60% of respondents found difficulty in differentiating whether the post operative reaction was inflammatory or infective. 59% of respondents give intravitreal antibiotics. Those who do not give say they are not familiar with the technique and do not want to risk a further procedure. 5% wanted to share the burden with the V-R surgeon.

The advent of clear cornea incision has led to an increase of endophthalmitis. Queried about this, 64% thought that this was not the case. 21% blamed the increase on clear cornea incision.

34% of the respondents had experienced cluster endophthalmitis.

More than half (54%) respondents could distinguish blebitis from bleb associated endophthalmitis

Preoperative Management in Cataract Surgery

Syringing for sac infection and conjunctival swab for culture sensitivity are a thing of the past as majority of the respondents do not perform these procedures routinely.

Antibiotics drops preoperatively and betadine drops on the table are universally followed.

However a sterile drape was not used by 33 % of respondents

Antibiotics either in BSS (36%) or intracameral antibiotics (22%) were used by a minority (15%).

Thus this survey brought out the following points regarding practice patterns of ROS members in managing endophthalmitis

- **41% of members still do not give intravitreal antibiotics on their own.**
- **A majority found it difficult to differentiate an infection from an inflammation.**
- **The preoperative practice patterns were in tune with the requirements of modern cataract surgery.**

The aim of this CME series is to update the ROS members on the advances in the field of endophthalmitis. The main emphasis is on postoperative endophthalmitis. There are 3 sections of the CME series : Management of post operative endophthalmitis, prevention of post operative endophthalmitis and other types of endophthalmitis.

I am indebted to all the contributors who have taken pains to write the articles. Special thanks to Dr. Lalit Verma, Hon. Gen. Secy. AIOS for his contribution and permission to publish excerpts from the AIOS CME series no 4. Special thanks to Dr. Manish Nagpal for providing the CD on the procedure of giving intravitreal injections. It is on the back page of this booklet.

Last but not the least I thank Dr. Virendra Agarwal Laser center for bank rolling this CME series.

Contributors

1. Dr. P. N. Nagpal	Ahmedabad
2. Dr. Lalit Verma	New Delhi
3. Dr. Gopal Verma	Jaipur
4. Dr. Pavan Shorey	Jaipur
5. Dr. Kamlesh Khilnani	Jaipur
6. Dr. Raj Kumar Sharma	Jaipur
7. Dr. Pankaj Sharma	Jaipur
8. Dr. Manish Nagpal	Ahmedabad
9. Dr. Anshu Sahai	Jaipur

Contents

Section 1 : Post Surgical Endophthalmitis

1. Endophthalmitis : An Overview	Dr. P N Nagpal	7
2. Post Surgical Endophthalmitis	Dr. Pavan Shorey	10
3. Post Surgical Reaction : Is it Inflammatory or Infectious?	Dr. Pavan Shorey	14
4. Cluster Endophthalmitis	Dr. Lalit Verma	17
5. Blebitis and Bleb Associated Endophthalmitis	Dr. Pavan Shorey	20
6. Flow Chart for Management of Endophthalmitis	Dr. Lalit Verma	21
7. Intravitreal Antibiotics : A Step by Step Approach	Dr. Kamlesh Khilnani	24
8. Vitrectomy in Endophthalmitis	Dr. Gopal Verma	27
9. The Endophthalmitis Vitrectomy Study	Dr. Manish Nagpal	29
10. Medico Legal Aspects of Endophthalmitis	Dr. Lalit Verma	30

Section 2 : Other Types of Endophthalmitis


1. Endogenous Endophthalmitis	Dr. R K Sharma	35
2. Traumatic & Childhood Endophthalmitis	Dr. R K Sharma	39

Section 3 : Prevention of Endophthalmitis

1. How to Avoid Post Operative Endophthalmitis	Dr. Pavan Shorey	45
2. Surgical Steps to Avoid Post Operative Endophthalmitis	Dr. Pankaj Sharma	48
3. How to Avoid Post Operative Endophthalmitis in Eye Camps	Dr. Anshu Sahai	51
4. Surgical Asepsis and Sterilization : CME series No. 4 (AIOS)		55

Availability of Vitreoretinal Surgeons with Vitrectomy Facilities in Rajasthan		64
---	--	----


Video CD on Technique of giving Intravitreal Injections	Dr. Manish Nagpal	
---	-------------------	--



SECTION 1

POST SURGICAL ENDOPHTHALMITIS

1. Endophthalmitis : An Overview	Dr. P N Nagpal	7
2. Post Surgical Endophthalmitis	Dr. Pavan Shorey	10
3. Post Surgical Reaction : Is it Inflammatory or Infectious?	Dr. Pavan Shorey	14
4. Cluster Endophthalmitis	Dr. Lalit Verma	17
5. Blebitis and Bleb Associated Endophthalmitis	Dr. Pavan Shorey	20
6. Flow Chart for Management of Endophthalmitis	Dr. Lalit Verma	21
7. Intravitreal Antibiotics : A Step by Step Approach	Dr. Kamlesh Khilnani	24
8. Vitrectomy in Endophthalmitis	Dr. Gopal Verma	27
9. The Endophthalmitis Vitrectomy Study	Dr. Manish Nagpal	29
10. Medico Legal Aspects of Endophthalmitis	Dr. Lalit Verma	30



Endophthalmitis : An Overview

Dr. P N Nagpal

In conversation with Dr. Pavan Shorey

Q. 1 How has the management of endophthalmitis changed from your early career as a V-R surgeon to the present.

A. The management of post operative endophthalmitis has undergone a sea change from what it was when we were in the beginning of our career. The remarkable reduction in the occurrence of this dreaded complications in these years highlights the preventive measures in the preparation of the patient and the more secure asepsis in the OT. In the past the incidence was more, presentations was more severe, diagnosis was late and the outcome of managements were poor. The occurrence of endophthalmitis meant loss of the eye, an end of the road. It was rare to save useful vision with topical, intravenous and the very painful subconjunctival antibiotics. The recognition of risk factors, intravitreal injections of combinations of new 3rd and 4th generation antibiotics, addition of steroids, improved methods to identify the causative organisms and their sensitivity to antibiotics and the introduction of vitrectomy procedures have altogether changed the outlook and outcomes

Q. 2 What according to you are the clinching signs and symptoms which help in early detection of endophthalmitis.

A. Pain and hazy glow of the pupil should always be taken seriously. Even a trivial looking complaint of pain should arouse suspicion and demand examination

Q. 3 A patient after cataract surgery is put on the slit lamp on the first post op. day: Flare, cells and a pupillary membrane: How will you differentiate whether it is inflammatory or infectious reaction?

A. At a fixed time after surgery(4hrs to 24 hrs) the eye should be subjected to slit lamp examination and standard created for ones own technique in ones own mind. Wherever in doubt repeat examination at frequent interval will distinguish the sterile inflammation from a infectious reaction by the changing severity. B-scan can help distinguish it as infective if the reaction involves the posterior part of the eye or as non infective if left over lens matter is detected.

Q. 4 Most of the patients of endophthalmitis who are referred to a V-R surgeon in India are severe having hypopyon, thick pupillary membranes and a vision of PL +ve / -ve. Why is this so? Is there a lack of awareness amongst the general ophthalmologist about this condition?

A. Shyness to accept the signs and symptoms, the embarrassment associated in acting fast to save the situation and general reluctance to ask the patient to quickly get in care of a vitreous surgeon causes the delay. High degree of suspicion and institution of intravitreal antibiotics and steroids can save many eyes from reaching a late stage

Q. 5 An anterior segment surgeon is convinced that the post op reaction is infectious: What is the indication that he should give intravitreal antibiotics

A. Once infection is suspected it is urgent to take a tap from vitreous for Gram staining, for KOH examination for Fungi, for culture and sensitivity. Tap taking should be followed by Intravitreal Injection of a combination of antibiotics covering both gram +ve and -ve. The patient should be quickly referred to the care of a Vitreous Surgeon

Q. 6 What intravitreal antibiotics are the drugs of choice in bacterial endophthalmitis

A. Vancomycin and Amikacin

Q. 7 Fulminant endophthalmitis after 7 days of surgery, how does one differentiate that it is bacterial or fungal endophthalmitis?

A. By the clinical signs and symptoms one can suspect fungal and then by taking a tap and Lab. Work up confirm the nature of etiology.

Q. 8 Is the microbiology of endophthalmitis in India any different from the west (The endophthalmitis vitrectomy study report)

A. Yes, Gram -ve bacteria and Fungi are more common.

Q. 9 After giving intravitreal injection what should be the follow up of such a patient and when should such a patient be referred to the V-R surgeon. Should a patient of endophthalmitis be hospitalized?

A. The haziness of glow of pupil and the gravity of symptomatology should be checked every 8 to 12 hours. If it is deteriorating or not responding the patient should be referred or considered for vitrectomy. If a patient is one eyed or is from outstation it is better to hospitalize such a patient.

Q. 10 What is your clinical experience regarding aqueous and vitreous sample cultures as most of the patients referred to a V-R surgeon are already on fortified antibiotic drops or have received an intravitreal injection.

A. The chances of getting any support from this exercise are less but it should still be done

Q. 11 What is the role of systemic and intravitreal steroids in endophthalmitis

A. Systemic antibiotics and steroids have no role, Intravitreal steroids must be given

except when it is proved or strongly suspected to be fungal.

Q. 12 Many anterior segment surgeons give sub conjunctival antibiotics: Are fortified antibiotic drops equivalent to sub conjunctival antibiotics.

A. Subconjunctival Injections have very little role when Intravitreal has been given. Moreover it is very painful. Fortified Antibiotic drops are useful. Do not forget Atropine 1% drops BD

Q. 13 What are the indications of vitrectomy in a case of endophthalmitis and to what extent should the vitrectomy be done

- Decreasing glow of the Pupil inspite of a Intravitreal injection
- Fading projection of light.
- Proved fungal etiology. Threatening or already occurred corneal involvement.

Q. 14 Even after vitrectomy, we find that there is no response to treatment (hypopyon persists, pupillary membrane reappears) What should the management be in such patients.

A. Revise the vitrectomy with IOL and Capsular Bag removal. Use newer combination of antibiotics taking hint from culture reports. Repeat Intravitreal antibiotic injections should be in diluted concentrations

Q. 15 What is the role of silicone oil in patients of endophthalmitis

A. After vitrectomy injecting silicone oil has following possible roles

- Reduces the chances of RD which otherwise is very high.
- Growth of bacteria is possibly retarded because SO is an inert material.
- Helps prevent the eye going into hypotony and Phthisis Bulbi.
- Because of the tamponade effect and clarity the post operative examination is easier. But it requires removal surgery after some interval

Q. 16 An issue of concern is the informed consent a V-R surgeon takes before doing the vitrectomy. Many cases of consumer court have occurred because the consent was provocative. How does one balance the interests of the anterior segment surgeon while taking such consent.

A. One should respect the colleague and that such a complication can occur in any situation. We should hang together rather than hang separately. We should be extremely careful and use balancing words and tone and not provocative words

Q. 17 How does one manage cluster endophthalmitis? Cluster endophthalmitis is a recurring feature in eye camps. Recently there was an episode of cluster endophthalmitis in Gujrat in an eye camp which led the Govt. to file an FIR against the Medical Supdt., the eye surgeon and the theatre staff. Should eye camps be stopped because all said and done sterility is compromised in eye camps.

A. Cluster occurrence requires management of - a. cases of endophthalmitis. b. public and community reaction. c. Exploration of etiology d. Prevention of recurrence by taking appropriate aseptic measures. The holding of camps has been stopped. You have to operate the cases at the base hospital

Q. 18 What is your opinion about the high volume phaco surgeons using the same phaco probe for doing 10-15 cases at a time

A. Ideally such a practice is incorrect and the surgeon should be dissuaded. In such situations multiple probes should be invested into and sterilised in between. The saline bottles used should also be changed after every case

Q. 19 What is your message to the general ophthalmologist who does not give intravitreal antibiotics (41% of ROS members do not do so according to our survey)

A. It is a pity. They must learn quickly. The state society should arrange hands on teaching at the appropriate centers.

Q. 20 How does one balance the charges of vitrectomy in endophthalmitis as the anterior segment surgeon expects a minimum charge or a no charge leading to compromises like using a used cutter etc

A. This is a personal relationship between the two surgeons. As such the vitrectomy surgeon deserves his payment. In this controversy the required treatment should go on and not get postponed. The patient should ideally pay the charges but the original surgeon can help his patient

Q. 21 Finally, your pearls to the general ophthalmologist to prevent endophthalmitis in his cases

A. Identify risk factors and take extra care in Immunosuppressed states, Diabetes. Lacrimalsac operated cases etc,

Keep a high degree of suspicion and look out for it while examining the eye post operatively specially if it was an eventful surgery

Take all kind of preventive measures including Povidone Iodine application and a subconjunctival injection of a broad spectrum Antibiotic

Do not overlook the pain complaint in the postoperative period. The eye must be examined even if it is middle of night

Discuss clearly with the patient about the urgency of management without creating any extra scare

At the slightest suspicion an intravitreal combination of antibiotics and steroid must be given immediately. Always consult a dilution chart for the various antibiotic and do not depend upon memory

Reference to Vitreoretinal Surgeons should be fast in case of poor response to intravitreal injection

Post Surgical Endophthalmitis

Dr. Pavan Shorey

Consultant Vitreo Retinal Surgeon, Jaipur Hospital

Post surgical endophthalmitis is one of the most devastating complications of Ophthalmic surgery; it is an ocular emergency and vision can be destroyed in a matter of hours. The Ophthalmic surgeon should be geared upto diagnose this entity promptly and institute measures that can salvage vision.

Incidence of Endophthalmitis

Since cataract surgery is the major ophthalmic surgery, the majority of endophthalmitis is after cataract surgery. Cataract surgery has undergone a high degree of technical refinement. This along with aseptic techniques and use of prophylactic antibiotics have brought down the incidence of endophthalmitis from 1.5 to 2% in 1900's to 0.06% to 0.09% in 1990s.

Since the introduction of clear cornea incisions the incidence of endophthalmitis has risen from 0.109% (1963-1999) to 0.265% (2000-2003). The relative rise of endophthalmitis with the advent of clear cornea incisions is as high as 2 to 3 times.

Why this increase?

Clear cornea incisions are less stable than limbal or scleral wounds. Initially, a beveled corneal incision will self seal, because hydrostatic pressure in the eye forces the inner lip of the wound to close. IOP drops in first few hours after surgery and the wound gapes allowing surface contaminants to enter the anterior chamber. This is more so in poorly constructed incisions.

Types of Post surgical endophthalmitis

There are 3 forms of post surgical endophthalmitis

1. **Fulminant:** Occurs within 4 days caused by gram negative bacteria, Staph. Aureus or streptococci.
2. **Acute:** Develops within 5-7 days caused by Staph. Epidermis, coagulase negative cocci, Fungi (rarely)
3. **Chronic:** May be bleb related or due to Propionbacterium Acnes, fungi etc.

Early detection of endophthalmitis

For early detection and prompt treatment of endophthalmitis one should be aware of the clinching signs and symptoms of this entity (Table 1)

When the patient is put on the slit lamp and anterior chamber reaction is detected, the dilemma the surgeon faces is : Is it inflammatory or infective? It is very important to follow up such a patient every 6 hours or so for the next 24 hours. Endophthalmitis of infectious origin progresses significantly while a sterile inflammation improves or does not show any worsening while on treatment.

Points towards a diagnosis of endophthalmitis

- (i) **Decreased visual acuity:** Blurring of vision is a presenting symptom in 94% of cases or a non improvement in vision to the desired level accompanied by anterior chamber reaction is the most frequently observed presentation.
- (ii) **Pain:** Out of proportion to that anticipated post operatively. It is significant that 25% patients do not have pain. Acute bacterial endophthalmitis (Onset 5-7 days) will show

TABLE 1
Typical Signs and Symptoms of Endophthalmitis

1. Decreased visual acuity
2. Pain (25% patients do not have it)
3. Hypopyon, anterior chamber reaction
4. Pupillary membrane
5. Poor or absent fundus glow

a sudden onset of pain and blurring of vision.

- (iii) **Other symptoms:** Blephrospasm, photophobia, excessive tearing
- (iv) **Hypopyon, pupillary membrane:** The presence of a hypopyon is a cardinal sign of infectious endophthalmitis. The hypopyon is dependant and in early cases may be missed. The iris pattern is lost and the pupil is resistant to dilation. Posterior synechia may be seen. Anterior chamber flare or cells may be mild to severe.
- (v) **Vitreous haze and Fundus glow:** Fundus details are evaluated by indirect ophthalmoscopy. Endophthalmitis vitrectomy study has graded the media haze depending upon the visibility of retinal details. This is evaluated by the indirect ophthalmoscope (Table 2). If visibility is poor and red reflex is absent ultrasonography could reveal vitreous opacities, vitreous membranes and choroidal thickening. A retinal detachment or vitreous haemorrhage may be present before cataract surgery but here the eye is quiet (Table 3).

Fungal Endophthalmitis: Usually present 2-4 weeks after surgery. Persistent iritis may be the only presenting sign. There may be growth of fungus over the iris surface or IOL. Whitish puff balls and vitreous strands are the cardinal signs of fungal infection.

Late endophthalmitis: Is due to slow growing less virulent bacteria. This occurs one to 12 months after IOL surgery. There is chronic indolent low grade iridocyclitis. 50% patients may have hypopyon and a classic white plaque may be seen between the intraocular lens and posterior capsule. This is typically caused by *Propiobacterium Acnes*.

Microbiology

Infectious endophthalmitis can be caused by both gram positive and gram negative bacteria.

Gram Positive bacteria: 76 to 90% of cases of culture positive post surgical endophthalmitis *Staph. Epidermis*, *Staph. Aureus*, *Strepto.*

TABLE 2

Media Clarity in Endophthalmitis

Grade 1	- Good Glow (Visual acuity 6/12)
Grade 2	- Visual acuity 6/12: Can visualize second order retinal vessels
Grade 3	- Can see some retinal vessels
Grade 4	- Vessels not seen, Red reflex present
Grade 5	- Red reflex absent

Pneumoniae, *Strept. Viridans* etc.

Gram negative bacteria: Account for 7 to 15% of cases *Pseudomonas Aeruginosia* is the most common followed by *Proteus*, *H. influenzae*, *Klebsiella* etc.

Fungal Endophthalmitis: Caused by *Aspergillus Fusarium*, *Candida*.

The Indian Situation

Three studies from North and South India¹⁻⁴ showed that the microbiological spectrum in India is different.

Gram positive endophthalmitis: 42-47%

Gram negative endophthalmitis: 26-42%

Fungal endophthalmitis: 13-17%

All these studies showed a low culture positivity (45-54%).

Laboratory Diagnosis: The mainstay of treatment of endophthalmitis is to identify the causative organism and target therapy towards them. 2 specimens are important : Aqueous and vitreous tap.

- (i) **Aqueous tap:** After local anesthesia, a paracentesis is done by a 26 or 30 gauge needle. The tuberculin syringe with the plunger on and the needle bevel pointing upwards is inserted into the anterior chamber and 0.1 ml of contents are withdrawal. This is then inoculated directly to the culture media in the O.T. some drops are used for gram stain, giemsa, gomori methanamine stain for fungi. Smear provide

TABLE 3

Conditions where no red reflex is present

- Retinal detachment (Long standing)
- Old vitreous haemorrhage
- Dislocated nucleus
- Severe posterior uveitis
- Fibrinous reaction (Post vitreoretinal surgery)

a rapid diagnosis but are less sensitive or specific than cultures.

(ii) Vitreous tap: Vitreous samples yield more positive cultures than aqueous taps. There are 2 ways to collect the vitreous specimen:

- a. **Aspiration** directly by a 22/23 g needle mounted syringe. In many cases the tap is dry due to formed vitreous and is fraught with danger of causing a retinal detachment.
- b. **Vitreous biopsy:** Is the best method to obtain a vitreous sample. It is obtained by attaching a tuberculin syringe to the suction line of the cutter. A sclerotomy is made for cutter by sclerotomy blade (20g) and the cutter inserted and activated. As the vitreous is cut, an assistant pulls on the plunger of the tuberculin syringe gently to obtain 0.2 to 0.3ml of specimen.

The specimen is directly plated into Blood agar, Chorolate agar, Seboursa media if available, thioglycolated broth.

Laboratory confirmed diagnosis is when

- Culture is defined positive if same organism grows in more than one medium or
- There is confluent growth on one or more solid media at inoculation site.

Culture of suture from suture abscess or infected suture tract is a must

Treatment of post surgical endophthalmitis

Remember

- (i) Endophthalmitis is an emergency and needs to be treated promptly.

- (ii) If suspected, treat as infectious endophthalmitis unless proven otherwise.
- (iii) Follow up the patient every six hours on an OPD basis.
- (iv) Outstation patients and one eyed patients need to be hospitalised.
- (v) Inform the patient about the diagnosis and management, tell about the guarded visual prognosis and take written consent and meticulously write the progress and follow up notes (medicolegal aspects)
- (vi) Record the time of onset of symptoms and presentation of the patient for treatment. Record if the patient is careless in follow up and is not following instructions properly (this probably will help if the case goes to the consumer court).

Treatment

1. Treat infection with broad spectrum antibiotics by local and intravitreal route
2. Decision regarding reference to a vitreo retinal surgeon for vitrectomy

1. Intravitreal antibiotics: Once a patient is suspected of endophthalmitis, intravitreal antibiotics are the best way of achieving high levels in the vitreous. All anterior segment surgeons should know how to give intravitreal antibiotics. There is no excuse in sending a patient to a V-R surgeon especially from a far off place without instituting this treatment

Drugs of Choice: 2 drugs are given which cover both gram positive and gram negative bacteria

- i. Injection Vancomycin: 1mg in 0.1ml
 - ii. Injection Ceftazidime: 2.25mg in 0.1ml
- or
- iii. Injection Amikacin: 400µ in 0.1ml

A detailed step by step approaches to intravitreal antibiotics will be dealt in detail in a subsequent chapter.

2. Systemic antibiotics: Though the EVS study failed to show any benefit of systemic intravitreal antibiotics on the course of

endothalmitis, most eye surgeons prefer to give systemic antibiotics. It is preferred to combine an antibiotic against gram positive bacteria (Ex Injection Vancomycin 1gm IV 12 hourly) with another against gram negative bacteria (Amikacin 250mg 8 hourly IV). Recently oral drugs like tab ciprofloxacin 750mg BD or Tab Gatifloxacin 400mg OD have shown to have good penetration of the vitreous.

3. Topical and subconjunctival antibiotics:

Sub conjunctival antibiotics are no longer used as topical fortified antibiotics work as well. In addition to pain, sub conjunctival haemorrhage, there is always a chance of penetrating the sclera in a soft eye.

preferred topical antibiotic :

Vancomycin drops: 50mg/ml

Amikacin drops; 20mg/ml

The preparation of fortified drops is given in a subsequent chapter.

4. Role of steroids:

Steroids need to be administered judiciously in a patient of post surgical endophthalmitis.

Advantages: Steroids decrease the tissue damage caused by inflammatory mediators, helping in limiting the tissue damage.

Disadvantages: Steroids will further deteriorate a fungal infection and enhance its growth. Hence if fungal infection is suspected it is better to avoid systemic steroids.

Route: Can be given systemically, locally as drops or by the intravitreal route

Comment: It is best to avoid steroids in the initial stages of infectious endophthalmitis. As the infection gets under control by local and intravitreal antibiotics and the eye responds to treatment (Ant. Chamber exudate decreases, fundus glow returns, corneal oedema decreases) local and systemic steroids can be added to treatment

5. Supportive therapy: In form of cyclopegia (Atropine drops), anti glaucoma agents if required, analgesics again if needed.

When do I refer a patient for vitrectomy

1. No response to intravitreal antibiotics and the clinical picture shows deterioration; severe endophthalmitis
2. Patient has perception of light only, no red reflex, corneal ring infiltrate
3. Suspected fungal infection
4. It is best to involve a V-R surgeon in the management of your patient of endophthalmitis. The responsibility is shared and will help in case the patient goes to the consumer court.

Follow up of a patient who has been given an intravitreal injection

1. Any worsening after intravitreal: Immediately refer to a V-R surgeon for a pars plana vitrectomy.
2. No worsening: Follow up for 24 to 48 hours. If there is improvement in form of decreased anterior chamber reaction and return of fundus glow: Medical treatment in form of fortified drops and cycloplegics is continued.

If there is no improvement: Repeat intravitreal or refer the patient for a V-R surgeon's opinion.

References :

1. Darek Y, T Das et al. Microbiological spectrum and susceptibility of isolates: Part I. Postoperative endophthalmitis. Am J Ophthalmology 1999;128:240-242.
2. Darek Y, T Das et al Microbiologic spectrum and susceptibility of isolates: Part II. Posttraumatic endophthalmitis Am J Ophthalmol 1999;128:242-244
3. AR Anand et al. Spectrum of aetiological agents of postoperative endophthalmitis and antibiotic susceptibility of bacterial isolates. Ind J Ophthalmol 2000;48:123-128
4. Amit Gupta, MS; Vishali Gupta. Spectrum and Clinical Profile of Post Cataract Surgery Endophthalmitis in North India. Indian J Ophthalmol 2002;51:139-45

Post Surgical Reaction : Is it Inflammatory or Infectious?

Dr. Pavan Shorey

Consultant Vitreo Retinal Surgeon, Jaipur Hospital

When you put your patient on the slit lamp on the first post operative day and find corneal oedema, anterior chamber reaction, hypopyon and membrane with a constricted pupil, a query immediately comes to the mind: Is it inflammatory or Infectious? It is essential to know the clinical features of both so that a differentiation can be done and a proper treatment instituted.

Post operative Endophthalmitis of the fulminant variety can present early and has grave prognosis and may lead to permanent loss of vision if not treated promptly.

Toxic Anterior segment syndrome (TASS) also known as sterile endophthalmitis has multiple causes including toxic effects from intraocular fluids, medications, IOLs, instruments, endotoxins and sterilization techniques.

Though the dictum that all post operative reactions should be treated as infective unless proven otherwise holds good, but if one can differentiate the two, we can save the patient from unnecessary infectious endophthalmitis treatment regimen.

Clinical Course

Infectious Endophthalmitis:

- Presents within 48 to 72 hours usually after surgery
- Pain is a presenting symptom (25% of patients do not have pain)
- Anterior chamber reaction and a hypopyon
- If fundus is seen: Retinal haemorrhages, retinal vasculitis may be seen.
- Deterioration is rapid

TASS:

- Presents sooner than infectious endophthalmitis: 12 to 24 hours after surgery

- Can have marked corneal oedema. This is characteristically "Limbus to Limbus".
- Moderate to severe anterior chamber reaction with cells, flare, hypopyon and fibrin sheets at times.
- Static

Visual Acuity

Infectious endophthalmitis: Ranges from perception of light only to 6/12-6/9 vision. Normally it is finger counting only and if left untreated deteriorates very fast

TASS: The visual acuity is decreased but the vision will not deteriorate as rapidly as in infectious endophthalmitis

Etiology

Infectious Endophthalmitis

- The primary source of bacteria is from the patient's ocular surface and adnexa.
- More virulent the bacteria (Gram positive or Gram negative organisms) more severe are the signs and symptoms
- Preoperative risk factors are blephritis, conjunctivitis, NLD block, secondary IOL polypropylene haptics, trans-scleral suture fixation, post operative wound defects
- Intra operative factors: Inadequate sterilization of eyelid, surgery longer than 60 min, vitreous loss, unplanned or inapparent ocular penetration.

TASS

- These cases are secondary to non physiological factors. In large volume surgeries, these cases tend to be clustered.
- It is a reaction to abnormal irrigating solutions, denatured viscoelastic, residual detergent in reusable equipment

- Reactions to finish, design, chemical structure or sterilization of IOLs.
- 1 case series reported sterile endophthalmitis due to Memory lens (Bausch & Lomb). The lens was withdrawn.
- Another series reported association between toxic endothelial cell destruction and intraocular benzalkonium chloride.
- Another case series reported sterile endophthalmitis after using refrigerated BSS

Treatment

Infectious Endophthalmitis: includes intravitreal antibiotics with or without pars plana vitrectomy

TASS: If one is certain about the diagnosis, local and systemic steroids must be started along with cycloplegics. The patient should be followed up closely

- Inflammatory reaction will respond dramatically to steroids.
- Monitor for any IOP increase and treat accordingly.
- Diffuse 'Limbus to Limbus' corneal oedema may not respond to any medical treatment and may require penetrating keratoplasty

Prevention of TASS

- Minimize the possibility of contamination with toxic substances
- BSS should be at room temperature
- pH and ionic composition of BSS should be checked and preservatives should be avoided
- All instruments should be carefully cleaned and dried prior to autoclaving
- Reuse of disposable tubes should be avoided
- Ultrasound water bath must be changed biweekly
- Phaco machines should be periodically checked for back flush or other sources of contamination

Case Studies

Case 1 :

TASS after cataract surgery in eyes that had previous Vitreoretinal surgery

A 51 year old woman had undergone retinal detachment surgery 5 years back in the right eye. 1 year later she developed scleral buckle infection for which the buckle was removed. On examination, she had a mature cataract in the right eye, accurate projection and the retina was attached on a B scan. She underwent uneventful clear corneal incision phacoemulsification with a foldable IOL. The first post operative day showed mild corneal oedema, pupillary membrane, a fibrin sheet in the anterior chamber, grade 1 vitreous haze. She had no pain. She was put on intensive moxifloxacin + dexamethasone combination drops, atropine drops and systemic steroids. The reaction cleared in a week's time.

Comment: Patients who have had previous vitreo-retinal surgery show some reaction after cataract surgery. The follow up should be 6 hourly initially. Inflammation will respond to treatment or remain stationary but infection will show a relentless progression.

Case 2 :

Severe TASS due to exogenous factors

A 60 year female had an uneventful phacoemulsification in the right eye and recovered 6/6 vision. She underwent phacoemulsification in the left eye 2 months later. On the first post operative day there was marked corneal oedema with descemet folds, marked anterior chamber reaction and a pupillary membrane. Following the dictum of treating every reaction as post operative infection she was put on intensive antibiotic drops and atropine. The second day the pupil dilated but the anterior chamber reaction and the pupillary membrane persisted. Local and systemic steroids were added. The pupillary membrane decreased in size and anterior chamber reaction disappeared over a period of 5 days. But the corneal oedema (Limbus to Limbus) persisted.

Over 3 months the patient developed bullous keratopathy and finally underwent penetrating keratoplasty with good recovery of vision.

Comment: This patient had a toxic anterior segment syndrome. It was found that the brand of irrigating solution had been changed on that particular day leading to a possibility of reaction to some constituents of the solution. Another

patient operated on the same day had corneal oedema which cleared with local steroids pointing to the fact that TASS patients may be clustered. Limbus to Limbus corneal oedema does not respond to medical treatment and the patient suffered for 3 months with pain due to bullous keratopathy before a decision for keratoplasty was taken.

Infection versus Inflammation

	Inflammation	Infection
Onset	First 24 hours	Usually 48 to 72 hours
Symptoms/Signs		
- Pain	Mild	Moderate to severe
- Vision decreased	Mild to severe	Severe
- Corneal oedema	Moderate to Severe 'Limbus to Limbus'	Mild to moderate
- A/c reaction	Moderate to severe	Moderate to severe
- Focal infiltrate	Rare	Commonly present
- Exudate	Whitish	Yellowish
- IOP	Normal to high	Low
Course	will remain stable or decrease with treatment	Worsen on serial examination
Etiology	<ul style="list-style-type: none"> - Abnormal irrigating Solution - Denatured visculastic - Residual detergents - Chemical residues 	<ul style="list-style-type: none"> - Corneal incision - Bacteria from patient - Ocular adenexa - Intraoperative factors
Treatment	Local & systemic steroids Cycloplegics	Intravitreal antibiotics and Vitrectomy

Cluster Endophthalmitis

Lalit Verma, Shaifali Gupta, HK Tewari, Dinesh Talwar, Avnindra Gupta

(Retina Management Group, Centre for Sight, New Delhi)

Post-operative endophthalmitis is catastrophic complication of intraocular surgery. Although its reported incidence has decreased significantly in the present era from 1% to 0.05%, it still remains a dreaded complication for all eye specialists.

Cluster endophthalmitis is a term defined as the occurrence of two or more than two infections at a time, or the occurrence of repeated post-operative infections under similar circumstances, i.e with the one surgeon, same staff, same operation theatre, same equipments, etc. These infections usually occur as a result of a breach in standard protocol of pre-operative, intraoperative and postoperative care. Cluster post-operative endophthalmitis is generally exogenous in origin. It can be either bacterial or fungal.

Risk Factors:

1. Contamination of water.
2. Multiple dose fluids and drugs.
3. Defects in sterilization of instruments.
4. Contaminated irrigating solutions.
5. Contaminated intra-ocular lenses.
6. Contaminated viscoelastics.
7. Hospital personal construction activity.
8. Poor operation theatre hygiene.

Measures to be taken in the event of Cluster endophthalmitis:

Depending on the number of cases, Green/Amber/or Red Alert is sounded and measures suggested include :

Green Alert : One case of endophthalmitis is noted, one in > or equal to 100 cases, or two in > or equal to 600 cases.

- Review the case.
- Discuss with colleague(s)
- Start immediate treatment.

- Make sure operation theatre and intraoperative tubing and fluids maintain sterility.
- Proper preoperative and postoperative care is taken.
- Continue operation theatre.

Amber Alert: One case in 75 cases, 2 cases in 300-500 cases, 3 cases in 700-800 cases.

- Examine the cases
- Discuss with colleague.
- Immediate treatment
- Send samples of conjunctival swabs and if needed of vitreous and anterior chamber also.
- Inform microbiologist to fully subtype the organisms grown.
- Reevaluate operation theatre.
- Fluids and tubings should also be sent for microbiological assessment.

Red Alert: 2 cases in < or equal to 200 cases, 3 cases in < or equal to 600 cases, 4 cases in < or equal to 800 cases

- Treat promptly and vigorously all endophthalmitis cases.
- Involve the hospital consultant microbiologist and hospital infection team at an early stage.
- Alert the lead clinician, clinical director and the medical director and submit a patient safety incident form in line with local reporting procedures. In due course this should trigger a report to the National Patient Safety Agency (NPSA) and the Commission for Healthcare Audit and Inspection (CHAI) (8).
- Consider reporting to the hospital clinical governance team.
- Give serious consideration to cessation of all intraocular surgery in the interests of patient safety whilst investigating the cause.

- Ensure colleagues are aware to ensure identification and reporting of further cases.
 - Keep detailed records of all action taken.
 - Document patient/surgical risk factors such as vitreous loss, blepharitis, nasolacrimal disease, immunosuppression, duration of surgery.
 - Try to identify common hospital factors such as draping and surgical technique, antibacterial prophylaxis, surgeon, nursing staff and other personnel, theatres, solutions, viscoelastics, intraocular lenses, disposable and non-disposable equipment, which autoclave used, and any changes in procedure or environment which may coincide with the outbreak. Microbiology may reveal a common organism or subtype. Track batch numbers of solutions, disposables and lenses. Consider microbiological culture of solutions or viscoelastics. Where appropriate, consider taking nasal and skin swabs from theatre personnel including surgeons. Note on which day of the week, which position on the list and at what time of day patients were operated.
 - Assess efficacy of cleaning and sterilization processes. Arrange for professional assessment of the hospital sterilizing service. Be alert to signs of failure of this process such as damaged or debris laden instruments, and blocked lumens.
 - Confirm that the theatre environment is to a sufficiently high standard with regard to cleanliness, air-flow and ergonomics. Repeat plate tests and airborne particulate matter test as appropriate in consultation with the infection control team.
 - Check theatre records to identify cases from other specialties or potentially 'dirty' cases which may have been operated in adjacent sessions.
 - Assess that all equipment and disposables are functional and used according to manufacturers instructions. Confirm single use where instruments are so designated. Ensure correct procedures are followed for cleaning and sterilization especially of phaco hand pieces.
 - Check that reasonable preventive measures are utilized with consideration of the above list.
 - A statistical approach may be necessary, comparing precise procedures, solutions, disposables, lenses and involved personnel between endophthalmitis and non-endophthalmitis cases in order to pinpoint a possible cause. Other statistical methods have been utilized to confirm and investigate an outbreak. Furthermore, an analytical technique new to medicine but widely used in the food industry known as Hazard Analysis Critical Control Points (HACCP) and which was originally developed by a group including NASA to ensure sterility of food used on space missions, may be used to identify key points in the healthcare process to target corrective action and monitoring.
- Carefully screen patients who present with ophthalmic complaints, especially postoperatively, and to educate them about which symptoms to report. Each of these identified risks is squarely within physician control and thus can be modified. A Witty (WIT-D) Approach to Avoiding Mistakes” proposes an easy-to-remember and effective strategy for improving the diagnostic process. Establish a prioritized differential diagnosis in order to rule out the **worst** case scenario; determine the **information** you need to obtain during the history and examination, or through studies, to rule that in or out; **tell** the patient and other health care providers to ensure that you are notified of all signs and symptoms that could help establish the diagnosis and determine the treatment plan; and **document** your decision-making process and follow-up plan.
- Deciding when to Postpone or Resume Surgery**
Faced with a cluster of either endophthalmitis, the surgical facility and the individual surgeon will need to decide whether or not it is safe to proceed with other scheduled ophthalmic cases at that location. Patient safety should be the

driving factor, and all patients must feel confident that the causative factors have been identified and addressed. At times, the surgery center may need the assistance of outside consultants in order to conduct the investigation and make the decision to cancel or resume procedures. Most elective cases can be postponed. Patients may be inconvenienced but will appreciate that you are working to ensure the best outcome for their eye condition. For urgent and emergent ones, you will need to find an alternative facility. If you do not have privileges at other facilities, you will need to refer the patient to an ophthalmologist who does.

Contact the affected patients: “The ____ surgical facility is evaluating a potential safety issue. For your protection, your surgery will be postponed OR your surgery will need to be done at _____ surgical facility. Since I do not operate at that facility, would you like for me to refer you or do you have another ophthalmologist you would like to see for your surgery?” When cause has been found out and proper sterilization has been ensured you can slowly start operating with few cases a day and if everything goes well you can resume surgeries as were before the outbreak but with full precautions.

Blebitis and Bleb Associated Endophthalmitis

Dr. Pavan Shorey

Consultant Vitreo Retinal Surgeon, Jaipur Hospital

One of the devastating complications of glaucoma filtering surgery is infection. This may lead to a localized infection of the filtering bleb or a full fledged endophthalmitis. The use of mitomycin has increased the incidence of blebitis and bleb associated endophthalmitis.

Blebitis: Consists of an isolated bleb infection with varying degree of anterior segment inflammation **without vitreous inflammation.**

It may represent an early stage of endophthalmitis and it is important to treat it early so that it does not progress to endophthalmitis.

Signs and Symptoms

Symptoms: Browache, headache, red eye may be seen 3 weeks before the diagnosis of blebitis is made. One must have a high degree of suspicion in patients who have undergone trabeculectomy.

Red eye, photophobia, pain, watering

Signs: White on red appearance

A white bleb is seen against a fiery red conjunctiva. It is milky white due to mucopurulent infiltrate in the bleb.

- Keratic precipitates, frank hypopyon may be seen
- Progression: is slow over days as compared to endophthalmitis over hours.

Risk Factors

- Use of mitomycin: This produces thinner cystic blebs which are susceptible to transmigration of the bacteria.
- Inferior bleb location
- Recurrent bacterial conjunctivitis
- Severe dry eye
- Combined operations

Treatment

- Fortified Vancomycin and Amikacin in severe blebitis
- Topical Moxifloxacin and Tobramycin otherwise
- Intensive regime (1 hourly)
- Monitor for vitreous involvement which means that blebitis is progressing to endophthalmitis.

Bleb Associated Endophthalmitis

The bacterial isolates here are different from post cataract endophthalmitis while patient's cataract endophthalmitis is predominantly caused by staphylococcus, the bleb related endophthalmitis is caused by streptococci and H. influenza which are more virulent. Hence the prognosis for bleb associated endophthalmitis is poorer. It calls for an early vitrectomy as compared to the post cataract endophthalmitis.

Onset: Late occurrence: Days or months after surgery

Presentation: Pain, redness decreased visual acuity over a period of hours.

Signs: Hypopyon, vitreous haze, loss of fundus reflex. The defining feature which distinguishes it from blebitis is the vitreous involvement.

Treatment: Early vitrectomy as it is caused by more virulent organism.

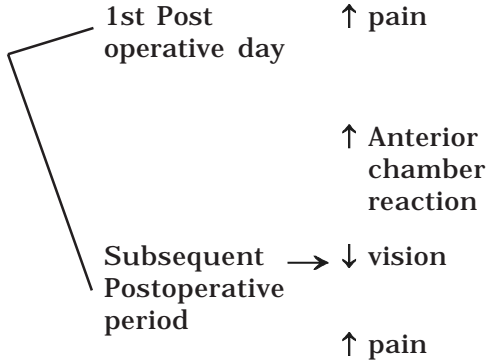
Conversion of blebitis to bleb associated endophthalmitis: The mean interval between blebitis and development of endophthalmitis is nine week according to a study. Thus it is important to follow up patients closely after resolution of blebitis since there is a high risk of developing bleb associated endophthalmitis.

Flow Chart for Management of Endophthalmitis

Lalit Verma, Shaifali Gupta, HK Tewari, Dinesh Talwar, Avnindra Gupta
(Retina Management Group, Centre for Sight, New Delhi)

WHEN DO YOU SUSPECT ENDOPHTHALMITIS?

Most important symptom



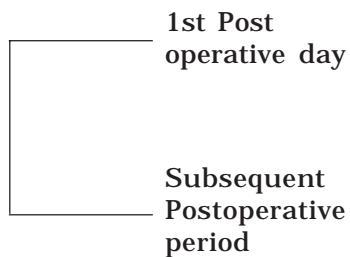
Surgeon's own cases are his Gold Standard

Familiarity with you own reaction on Slit Lamp essential

Deterioration following improvement

PAIN → in all cases? No → absent in 25%

Most important Sign



* ↓ glow on distant Direct Ophthalmoscopy

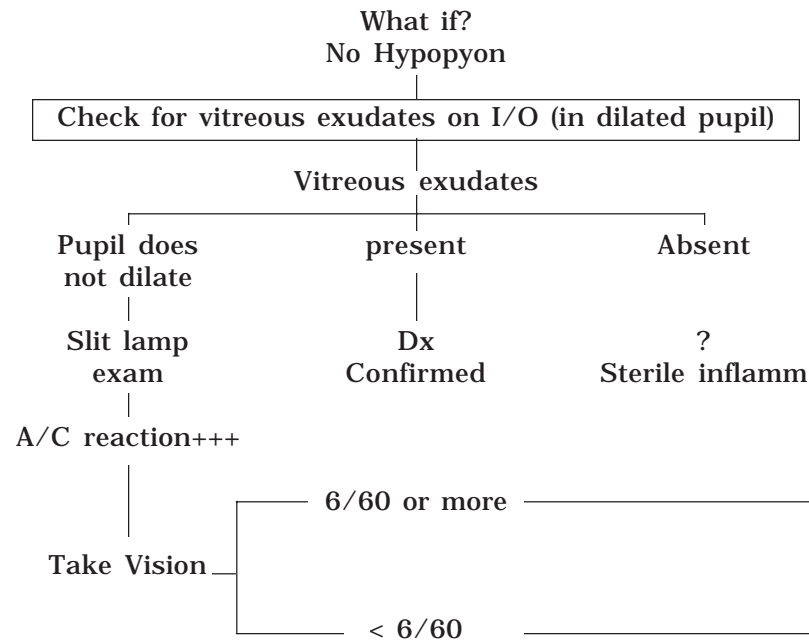
-- very high sensitivity Low specificity (other causes also)

* exudates in Vitreous (I/O) →

Almost 100% specific

WHEN DOES YOUR DIAGNOSIS BECOME DEFINITIVE/CONFIRMED?

Presence of Hypopyon + Vitreous Exudates on Indirect Ophthalmoscopy



ROLE OF USG

- * Not for making Dx
- * Helps in decisions regarding surgical intervention
- * R/o other cause (masquerade syndrome)

CASE SITUATIONS

1. Good glow (Disc hazily seen - AC reaction ++/+++ and no hypopyon

- ↓
• What to do?
Intravitreal injection OR Topical + S/C + I/V?

NO INTRAVITREAL INJECTION IF

- No hypopyon
- Fundus Glow good - details still seen
- A/C reaction predominant

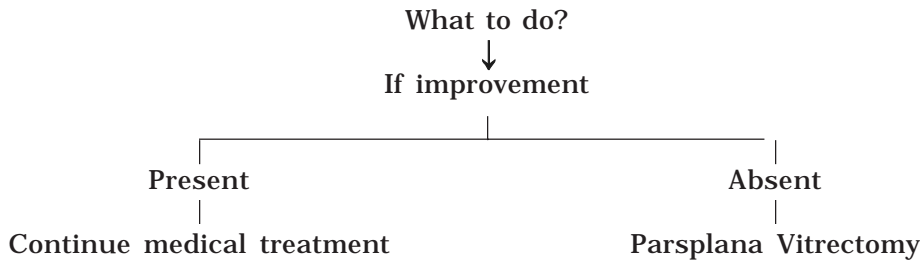
2. Partial Response

Hypopyon disappears after intravitreal injection

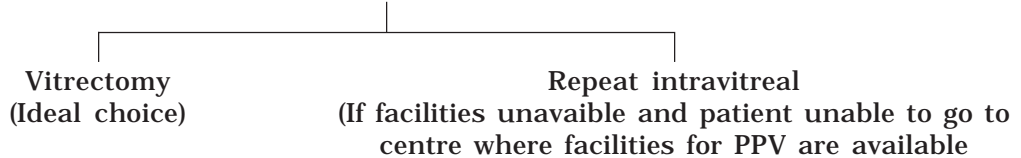
A/C reaction +++/++++

- ↓
• What to do?
Repeat intravitreal injection not necessary
(Continue conservative treatment)

3. Results of vitreous C/S not corresponding with intravitreal antibiotic injection



4. No response to intravitreal antibiotics : What to do?



5. Initial VA _____ P1 +ve
With _____ Hypopyon
With _____ No glow

- ↓
• What to do?
Still give intravitreal antibiotic injection unless facilities for immediate vitrectomy available.

Intravitreal Injection : A Step by Step Approach

Dr. Kamlesh Khilnani

Associate Professor, Ophthalmology, S.M.S Hospital, JAIPUR

The only certain way to attain therapeutic concentration of a drug in the vitreous is by intravitreal injection. The danger of this procedure is probably overstated. It is generally safe when prepared and administered carefully. It perfectly falls under the domain of general ophthalmologist, to administer intravitreal injection. An intravitreal injection by an ophthalmologist working in periphery and prompt referral to vitreoretinal surgeon may be vision saving in case of endophthalmitis.

Choice of Intravitreal Antibiotics in Endophthalmitis

Ideally, identifying causative agent, its sensitivity and then giving intravitreal injection is desirable. However this may not be possible in all cases as it is time consuming and delay due to this may affect patient's visual prognosis adversely. As a single antibiotic that covers all organisms is not available, a combination of two drugs, one with activity against Gram +ve organisms (e.g. Vancomycin hydrochloride) and another with activity against Gram -ve organisms (Ceftazidime hydrochloride or Amikacin sulfate) is the treatment of choice.

Dexamethasone acetate may be added as a third drug depending on the extent of inflammation. If clinically, fungal endophthalmitis is suspected then Amphotericin B should be given.

Assessment before Intravitreal Injection

1. The wound integrity should be assessed - if required sutures applied to make the wound water tight.
2. Any infected sutures or suture abscess should be removed.
3. Status of lens (aphakic / pseudophakic or phakic) should be determined - this decides the site of pars plana entry and in aphakic patients with broken anterior vitreous phase a trans-limbal route may be adopted.

4. Intraocular pressure should be assessed, if possible measured (preferably with non contact tonometry) and appropriate measures should be taken accordingly.
5. USG should be performed to rule out choroidal or retinal detachment.

Administration of Intravitreal Injection

1. INFORMED CONSENT should be taken before the procedure.
2. It should be given under all aseptic precautions in the OPERATION THEATRE.
3. MATERIALS REQUIRED :
 - i. Clean glass slides
 - ii. Culture plates (nutrient agar/chocolate agar/sabouraud's medium)
 - iii. Tuberculin syringes
 - iv. 30G / 26G ½ inch and 23G 1 inch needles
 - v. Antibiotic vials
 - vi. Surgical tray (lid speculum/sterile cotton tipped applicator/caliper/fixation forceps)
4. CHOICE OF ANAESTHESIA:
 - Topical instillation of 0.5% Proparacaine hydrochloride along with facial block should be given.
 - Peribulbar/retrobulbar block should be avoided.
 - General anaesthesia preferred in children and uncooperative patients.
5. STEPS OF THE PROCEDURE
 - a. Patient is made to lie supine on the operation table.
 - b. Surgical site is painted and opsite applied: the following method should be adopted -

Paint the periocular region with Povidone-Iodine 5% (betadine) solution. The horizontal extent must be from midline to

the beginning of auricle and the vertical extent from the hair line to a line passing horizontally from angle of mouth. Wait for it to dry for about 2 mins. Scrub lid margin with betadine applicators. Instill betadine drops into the cul de sac. Wash after 1 min with normal saline. Again paint the above mentioned region and let the region dry.

Apply Opsite or other similar adhesive taking particular attention to ensure its tight adherence at the medial canthus, nasal bridge and naso-labial fold. Keep the adhesive slightly redundant over the open eyelids while applying. However prevent corneal touch. Lift the temporal edge of adhesive at the lateral canthus and make a horizontal slit upto the medial canthus. At the medial canthus cut in a V or T pattern. Insert the eyelid speculum in such a manner that the eyelid margin and eyelashes are wrapped within the edges of the adhesive.

- c. Adequate visualization of the injection site is made.
- d. The injection is given transconjunctivally, in any quadrant which increases the ease of injection.
- e. The distance from limbus is measured and marked -

- i. Aphakic: 3mm
- ii. Pseudophakic: 3.5mm
- iii. Phakic: 4mm

- f. Obtaining vitreous samples

A sample of vitreous is the most important source to know the organism causing endophthalmitis. The sample should be obtained before injecting the antibiotics. This provides undiluted specimen and provides space for antibiotics. It also serves to decrease the intraocular pressure prior to the injection.

A 23G needle should be used for the same and if the vitreous is fluid, 0.2 to 0.3 ml is

gently aspirated. If a vitreous sample is not taken, 0.2ml of aqueous is tapped to decrease the intraocular pressure as well as for gram stain and culture sensitivity.

Sometimes aspiration may not provide adequate samples, especially if the vitreous is denser or contains inflammatory membranes. It is also possible that most of the Retinal detachments following intravitreal injection are a result of vitreous aspiration rather than the injection itself.

- g. Injection of the drugs

- i. The drugs to be given intravitreally should be prepared afresh by the surgeon himself with full aseptic precautions. This ensures proper dosage of the drugs as low dosages are ineffective and high dosages can cause retinal toxicity.

- ii. The globe should be fixated using a cotton tipped applicator in the quadrant opposite to the site of injection. Alternatively a fixation forceps may be used but there are chances of tearing the inflamed conjunctiva and hemorrhage.

- iii. The 26/30G needle attached to the tuberculin syringe loaded with the drug is then gradually inserted at the marked site. The beveled edge of the needle should be facing upwards towards the surgeon. The direction of penetration should be towards the anterior or mid vitreous.

- iv. The drug should be injected slowly in a drop by drop manner which can be obtained by rotating the plunger instead of pushing it directly, thus avoiding jet formation.

- v. As it is prudent to avoid multiple entries into the globe, the second injection should be given through the initial needle. This is achieved by stabilizing the initial needle with a

- forceps and then replacing the syringe.
- vi. The needle is gradually withdrawn.
 - vii. The intraocular pressure should be assessed in the end.
 - viii. Subconjunctival injection of antibiotics is given.
 - ix. Pad and patch done.

h. Postoperative management

- Pad and patch for 2 hrs
- Tab. Acetazolamide 250mg bd.
- Removal of pad and patch after 2 hrs and instillation of topical antibiotics initiated.

6. NUMBER OF INJECTIONS: 2, at the most 3 repeated after 48hrs

7. COMPLICATIONS OF THE PROCEDURE

- i. Elevated intraocular pressure
- ii. Intraocular hemorrhage including hyphema
- iii. Drug induced retinal toxicity
- iv. Retinal detachment
- v. Risk of cataract in phakic eyes due to inadvertent contact by the needle

8. INDICATIONS FOR VITRECTOMY AFTER INTRAVITREAL INJECTION

- i. Worsening despite a proper injection
- ii. No response to two repeat intravitreal injections
- iii. Development of complications like Retinal detachment
- iv. Inadequate drug dosage due to faulty preparation

TABLE: COMMONLY USED DRUGS FOR INTRAVITREAL INJECTION
(DILUENT – NS or sterile water for injection unless otherwise stated)

DRUG	VIAL SIZE	INITIAL DILUENT (ml)	INITIAL CONC. OBTAINED (mg/ml)	ALIQUOT (ml)	DILUENT (ml)	FINAL CONC. (mg/ml)	FINAL DOSE ORDERED	REMARKS	SPECTRUM COVERED
Vancomycin hydrochloride	500mg powder	10	50	0.2	0.8	10	1mg/0.1ml	Do not combine with other drugs, as it precipitates	Gram +ve
Ceftazidime hydrochloride	500mg powder	10	50	0.5	0.5	25 (has 22.5mg of active ingredient)	2.25mg/0.1ml	No retinal toxicity, more effective in acidic & hypoxic conditions	Gram –ve including pseudomonas
Cefazoline hydrochloride	500mg powder	10	50	0.5	0.5	25 (has 22.5mg of active ingredient)	2.25mg/0.1ml	-	Gram +ve & most staphylococcus
Amikacin sulfate	100mg in 2ml	8	10	1	1.5	4	0.4mg/0.1ml	4 times less retinotoxic than gentamycin	Gram –ve & most staphylococcus
Amphotericin B	50mg powder	10 (5% Dextrose)	5	0.1	9.9 (5% Dextrose)	0.05	5µg/0.1ml	-	Antifungal
Dexamethasone acetate	8mg in 2ml	-	4	-	-	4	0.4mg/0.1ml	-	Anti inflammatory

Vitreous Surgery in Endophthalmitis

Dr. Gopal Lal Verma

Eye Surgery & Laser Centre, C-401, Malviya Nagar, Jaipur

Surgical management of endophthalmitis by pars plana vitreous surgery is crucial in salvaging the eye in endophthalmitis. Pars plana vitrectomy has a definite role under following circumstances.

Immediate vitrectomy

1. Post surgical endophthalmitis where eye has not responded to intravitreal vancomycin, amikacin and dexamethasone.
2. Post surgical endophthalmitis cases presenting vision less than hand movements as defined in endophthalmitis vitrectomy study¹.
3. Earlier aqueous/vitreous tap microbiology shows gram negative organisms.
4. Post traumatic endophthalmitis, foreign body injuries with retained intraocular foreign body.
5. Fungal endophthalmitis.

Deferred vitrectomy

The purpose of deferred vitrectomy is to address late complications of endophthalmitis. The common indications are:

1. Opaque membranes in vitreous interfering patient's vision.
2. Chronic endophthalmitis with low virulence organisms .
3. Cyclitis and hypotony .
4. Recurrent uveitis, low grade inflammation, cystoid edema of macula.
5. Toxic anterior segment syndrome.
6. Posteriorly dislocated Intraocular lens, metallic or glass foreignbodies.
7. Rhegmatogenous retinal detachment.

A case of endophthalmitis scheduled in emergency for vitrectomy should have a fair trial

of intravitreal vancomycin, amikacin, dexamethasone preceding twelve hours before actual start of vitrectomy, depending on surgeons experience and clinical judgement. This step is fairly indicated in cluster infections occurring in single day volume surgery as seen in eye camps. This would save more eyes undergoing parsplana vitrectomy and its complications.

Basic steps involved in pars plana vitrectomy are similar except that detailed visualization of intraocular instruments and tissues is a challenging task at the beginning of vitrectomy.

The surgery is done under peribulbar block and intravenous sedation observing all asepsis preoperative and intraoperative preparation.

If the previous surgery wound is necrotic, wound margins thoroughly cleaned, sutures if any ,applied fresh . Standard three port sclerotomy made in usual manner but MVR blade should be very sharp else it may detach ciliary body and choroid. It is advisable to have curved Wilson canula or 6mm long infusion illuminated cannula as ciliochoroidal region is edematous and thickened and covered with exudates impeding free flow of infusion fluid in vitreous cavity. In a hazy cornea debridement of central 3 to 4mm epithelium is done with a spatula. Hypopyon and exudates from anterior chamber are cleaned from limbal route. It is not mandatory to explant the intraocular lens² unless the sterility of implant is questionable. Explantation of intraocular lens is recommended in fungal endophthalmitis.

Before begining of infusion , vitreous cutter is activated and cut vitreous is manually aspirated by 1ml syringe . Thus an undiluted vitreous sample of 0.5ml or 0.75ml is collected and sent for microbiology examination . After obtaining undiluted vitreous specimen, infusion fluid is kept on and vitreous cutter is activated at high rate and aspiration level is kept minimum.

Anterior and central vitreous is removed first, followed by posterior central vitreous. No attempt is made to enter vitreous base. Once major vascular arcade, optic disc and macula is visible, no posterior hyaloid cleaning is done. Foci of microabscesses are not manipulated as it will lead to iatrogenic hole formation in necrotic edematous retina. This will complete the steps of core vitrectomy. However in fungal infection a radical approach is needed where removal of intraocular lens is combined with excision of capsular bag and zonular apparatus. With the availability of cost prohibitive broad spectrum antifungal agent like voriconazole surgeon may have a discretion of sparing intraocular lens and capsular bag. At the conclusion of surgery one tenth dilution of standard intravitreal doses of amikacin that is 40micro gram and one fifth dilution of standard intravitreal doses of vancomycin that is 200microgram are injected after closure of all the sclerotomy ports. The antibiotic vancomycin or ceftazidime may also be added to vitrectomy infusion fluid in non toxic doses³. Keeping in mind rapid clearing of antibiotics from intraocular cavity in vitrectomised eyes, vancomycin 25mg subtenon and amikacin 50mgm is deposited subconjunctivaly. Post operative topical cycloplegic and 4th generation fluoroquinolin like Gatifloxacin or Moxcilin drops 4hourly. Oral ciprofloxacin 750mgm bid given. In suspected

fungal endophthalmitis oral Fluconazole 200mgm bid or oral Voriconazole 400mgm bid started. Intravitreal injection of 5microgram Amphotericin-B is given where fungal infection is strongly suspected.

The advantages of vitreous surgery in endophthalmitis are:

1. Minimises bacterial or fungal load in vitreous cavity.
2. Removes exo and endo toxins, viral particles and purulent material from intraocular cavity.
3. Better dispersion of antibiotics
4. Removes media opacities.

Complications

1. Failure to achieve control of infection and inflammation .
2. Post surgical hypotony and phthisis bulbi.
3. Rubeosis.
4. Iatrogenic retinal tears and retinal detachment which may be difficult to manage.

Conclusion

Vitrectomy has a definite role in management of nearly all types of endophthalmitis. The role is more defined in traumatic and fungal endophthalmitis and also endophthalmitis due to gram negative virulent micro organisms.

References :

1. Doft BH. The endophthalmitis vitrectomy study (EVS) Arch Ophthalmol 109:487-489, 1991.
2. Hopen G, et.al. Intraocular lenses and experimental bacterial endophthalmitis. Am J Ophthalmol 94:402-407,1982.
3. Paymen GA, Dau M. Prophylaxis of endophthalmitis. Ophthalmic Surg 25: 617-674,1994.

The Endophthalmitis Vitrectomy Study

Dr. Manish Nagpal, Dr. Anil Patil

Retina Foundation, Ahmedabad

In 1995, the Endophthalmitis Vitrectomy Study (EVS) Group published the results of a multicenter randomized clinical trial evaluating the roles of pars plana vitrectomy and systemic antibiotics in the management of postcataract extraction endophthalmitis. The article demonstrated that immediate vitrectomy was not necessary in patients with visual acuity better than light perception at the time of presentation, but that it was of significant benefit for those with light perception only. In addition, the use of systemic antibiotics did not enhance final visual acuity or media clarity.

The most commonly cultured microorganism in acute postoperative endophthalmitis is *Staph. epidermidis* which tends to be less virulent than other causes such as *Staph. aureus*, *Streptococcus* species, and gram-negative rods (*Serratia*, *Proteus*, and *Pseudomonas*). The endophthalmitis vitrectomy study (EVS) found that 69 percent of the patients with endophthalmitis had confirmed bacterial growth on culture. About 70 percent of the patients with positive cultures were infected with coagulase-negative microorganisms (mostly staph epidermidis), 10 percent with *Staph. aureus*, 9 percent with *Streptococcus* species, 2 percent with Enterococcus, 3 percent with other gram-positive species, and finally 6 percent with gram-negative species. This study confirmed that the more virulent organisms caused signs and symptoms of endophthalmitis to appear earlier than organisms of low virulence. The EVS patients in whom symptoms developed within two days of surgery were approximately twice as likely to have either a gram-negative or "other" gram-positive organism as the cause of endophthalmitis. Other significant findings that were correlated to a more severe infection included corneal infiltrate, cataract wound abnormalities, afferent pupillary

defect, loss of red reflex, and initial light perception only vision. These findings were all more highly associated with gram-negative or "other" gram-positive isolates. Surprisingly, eye pain was not found to be a significant factor in discriminating the types of organisms isolated in these patients. However, this group also concluded that the visual acuity at initial presentation appeared to be more useful than biologic factors in predicting visual outcome and favorable response to vitrectomy in acute bacterial endophthalmitis.¹⁸

Applying EVS to clinical practice:

The EVS has had a significant impact on the management of postcataract surgery endophthalmitis. Most patients are now treated in the office with vitreous tap and intravitreal antibiotic injection rather than pars plana vitrectomy, and most can now be managed as outpatients and do not require hospitalization with intravenous (IV) antibiotics.

However, it is important to limit these conclusions to postcataract surgery endophthalmitis and not to generalize them to infections that are associated with filtering blebs, are delayed after cataract surgery, follow trauma, or are metastatic from an endogenous source. These circumstances may produce a different and more virulent spectrum of organisms, such that the EVS recommendations do not hold. Decisions about the use of vitrectomy should be based on the severity of the vitreous involvement or the difficulty in obtaining a positive culture rather than on initial visual acuity. The use of systemic antibiotics remains the standard of care for posttraumatic endophthalmitis and is also necessary for most cases of endogenous endophthalmitis.

Medico-Legal Aspects of Post-Operative Endophthalmitis

Lalit Verma, Shaifali Gupta, Dinesh Talwar, Avnindra Gupta, HK Tewari
(Retina Management Group, Centre for Sight, New Delhi)

Endophthalmitis occurs in best of hands in best of set ups. Only people who do not get endophthalmitis are those who do not operate

For endophthalmitis to occur what is required is a breach or a cut in integrity of ocular coats and introduction of microbial inoculum. We all know during intraocular surgery both of these happen. Inoculum means microbiological load resulting in endophthalmitis. Inoculum can be of various sizes and types. To measure size of the inoculum one can use the concept of colony forming unit (CFU). It is a measure of viable cells in which a colony represents an aggregate of cells derived from a single progenitor cell. CFU is used to determine the number of viable bacterial cells in a sample per mL. Hence, it tells the degree of contamination in samples of water, vegetables, soil or fruits, or the magnitude of the infection in humans and animals. It is different from the direct microscopic counts that includes both dead and living cells. Types of inoculum mean different types of microorganisms. Like for Staph. aureus if 19 colony forming units enter intravitreally or 50 colony forming units enter anterior chamber during surgery, endophthalmitis will occur. For Pseudomonas if only 5 colony forming units reach vitreous cavity or 197 colony forming units reach anterior chamber fulminant infection results.

Corneal incision is at least three times more potent than tunnel incision for causing endophthalmitis. This is a well substantiated fact that it is the valvular effect of the incision which keeps it isolated from the nuances of conjunctival flora. If there is a compromise in valvular effect there is a possibility that there is a suction effect and more inoculum can enter the eye and there are more chances of endophthalmitis.

Intra-ocular infection has always brought disrepute to the ophthalmologist and this problem

is not only rampant at eye-camps but also in hospitals, which include the five star ones. Only surgeon who does not have endophthalmitis is the one who does not operate. The problem is general and it is not the surgeon who is to be blamed although he is responsible for surgery. Despite the best possible care, mishaps cannot always be avoided because the error in one link of the entire chain may sometimes result in a disaster.

But in the court of law if you have a misfortune of infection then how to save yourself?

- Record all findings including vision-including projection of rays, intraocular pressure, status of cornea, anterior chamber reaction, pupillary reaction, details of iris, IOL (if present) and fundus. Get B-Scan ultrasound done if fundus cannot be seen at all.
- Record them daily and keep a copy with you.
- Do not do telephonic treatment. e.g if patient calls up in the night and complains of pain, redness, watering and if you tell him to continue or add steroid drops, then this is asking for a disaster. That means that instead of giving telephonic treatment tell the patient to go to nearby ophthalmologist available and show to him.
- Patient who is on treatment for endophthalmitis, see him daily and always write on the prescription to report SOS. If patient is from far flung area write on his card or prescription slip that in case of any pain or redness or decreased vision or unusual symptoms report to nearest ophthalmologist and mention "do not ignore."
- Even at the cost of please document, document and document.

- When in doubt seek peer review, refer to retinal surgeon or hospital.
- Involve multiple people or hospitals to safeguard you.

Greatest malpractice risk associated with endophthalmitis- Analysis of claims show that liability arises from a delay in diagnosis or treatment, including a delay in referring the patient to a vitreo-retinal specialist.

To reduce the risk of delay in diagnosis-

- If the surgery was complicated and took a long time or required extensive instrumentation, you should have a higher index of suspicion for the development of endophthalmitis.
- Give all patients written discharge instructions stating the symptoms that warrant contacting you (blurred vision, red eye, pain, photophobia).
- Educate your staff members who handle telephone calls about the risk of endophthalmitis. Instruct them to schedule emergent appointments for such patients. Err on the side of patient safety when deciding to treat over the phone versus examining the patient.

To reduce the risk of delay in treatments-

- Document your decision making process in the medical record, especially when the patient calls with symptoms of a possible infection.
- Obtain a thorough interval history and perform and document the clinical examination. Note the presence and absence of signs of endophthalmitis (the cardinal sign is intraocular inflammation greater than expected for that point in the recovery process.)
- If in doubt, consult with and/or refer patients to a vitreo-retinal specialist for management.

Measures to take to reduce liability:

- During the informed consent discussion (a must for all surgeries), warn patients about the risk of infection and possibility of vision loss. Emphasize the risk specially if the patient has diabetes or is immunosuppressed. You

have to tell the patient and relatives that you are going to do the best and leave no stone unturned in this regard - but still complications including infection happen in the best of hands and in best of set ups including in all developed countries. Explain in raw language- where ever there is a cut (however small it may be), bacteria or other organisms can enter.

- Have a prudent follow up plan, especially in the symptomatic patient, and ensure that the patients make the appointment before leaving your office.
- Diligently follow up on all the patients who miss or cancel appointments, again ensuring that they understand that not receiving appropriate treatment could result in blindness.
- Carefully instruct patients to call you immediately if vision loss, pain or other ocular symptoms develop before their next scheduled visit.
- Make sure to DOCUMENT, DOCUMENT, DOCUMENT.
- Take anterior segment and fundus photographs, if possible.

After the catastrophe in Khujra, practically a National Alarm was created and Supreme Court intervened & passed certain guidelines for eye camps:

1. Qualified, experienced ophthalmic surgeons registered with Medical Council of India or any State Medical Council should only perform the operations. Camps should not be used as training ground for post-graduate students, and operative work should not be entrusted to post-graduate students.

View point: *Students or fellows or inexperienced doctors should operate under guidance and avoid doing surgery in one eyed and other high risk patients.*

2. There should be a pathologist to examine urine, blood, sugar etc.

3. It is preferable to have a dentist to check the teeth for sepsis and a physician for general medical check-up.

View point: *Physical presence of pathologist is not essential. What is required is a proper work up of patients, proper preoperative evaluation, and clearance from physician or cardiologist if needed.*

4. All medicines to be used should be of standard quality duly verified by the doctor in-charge of the camp.

View point: *This is of utmost importance especially so, for irrigating fluids, viscoelastics, sutures, intraocular lenses etc.*

5. The necessity of maintenance of the highest standards of aseptic and sterile conditions at places where ophthalmic surgery - or any surgery - will be conducted was emphasised. The Supreme Court said: "The necessity of

maintenance of the highest standards of aseptic and sterile conditions at places where ophthalmic surgery - or any surgery - is conducted cannot be over-emphasised.


View point : *It is not merely on the formulation of the theoretical standards but really on the professional commitment, with which these are implemented, followed and periodically reviewed and appropriate action taken, that the ultimate result rests.*

Remember, a surgeon is best known or assessed by the way he handles complications or unusual situations. The way he talks to the patient, his relatives is of paramount importance. All the problems arise when patient's expectations are sky high and he is not explained the reality by the treating surgeon and someone else tells, makes the patient aware or even instigates (not a uncommon situation)

SECTION 2

OTHER TYPES OF ENDOPHTHALMITIS

- | | | |
|--|----------------|----|
| 1. Endogenous Endophthalmitis | Dr. R K Sharma | 35 |
| 2. Traumatic & Childhood Endophthalmitis | Dr. R K Sharma | 39 |



Endogenous Endophthalmitis

Dr Raj Kumar Sharma, MS, FRF, FCLI Vitreoretinal Surgeon

Dr Sunil K Thakur, MS, Vitreoretinal Fellow

Sahai Eye Hospital and Research Centre

Definition : Inflammation of the internal layers of the eye resulting from intraocular colonization of the infectious agents with an exudation into the vitreous cavity. Colonization occurs as a result of hematogenous dissemination of the organisms, as the presence of septic foci anywhere in the body will cause dissemination of the microorganisms in the blood and it will reach in the choroidal vasculature resulting in the endophthalmitis in patients with poor immune response.

Types :

Bacterial Endogenous endophthalmitis

Fungal Endogenous endophthalmitis

Etiology:

Predisposing factors in a patient with

1. Immunocompromised status
2. Prolonged alimentation
3. IV drug abuse
4. Risk factors

Indwelling catheters, systemic antibiotics, major surgery, malignancies, diabetes mellitus, chronic alcoholism, liver disease, organ transplantation, corticosteroid therapy, puerperal sepsis.

Recently fungal endogenous endophthalmitis has been described in healthy patients after receiving presumable contaminated intravenous dextrose infusions.

Endophthalmitis in any case in absence of any kind of intraocular surgery/trauma in the past with no filtering bleb and bilateral involvement in any patient should have a high suspicion of endogenous endophthalmitis.

Bacterial endogenous endophthalmitis:

Perhaps the rarest form of endophthalmitis.

Beware: very severe, extremely rapid progression, dismal visual prognosis.

Several organisms are reported e.g. *N. meningitides*, *Streptococcus pneumoniae*, *Staphylococcus aureus*, *Bacillus cereus*, gram negative (*E coli*, *Pseudomonas*, *Proteus*), and *Klebsiella*.

Clinical presentation of endogenous bacterial endophthalmitis:

Classification given by Greenwald and colleagues

Four classes

1. Anterior focal: excellent prognosis
2. Posterior focal
3. Anterior diffuse
4. Posterior diffuse: very poor prognosis; can progress into no PL with CRAO and may progress into a fulminant and life threatening panophthalmitis.

Bilateral in 25% cases, bilaterality favours the endogenous nature of infection in absence of any trauma/surgery.

Symptoms: decreased vision in an acutely ill (septic patient), an immunocompromised host or an i.v. drug abuser. Pain in these cases is less in comparison to the post-traumatic or postoperative endophthalmitis.

No history of recent intraocular surgery.

Critical signs: vitreous cells and debris, anterior chamber cell and flare and/or a hypopyon in a high risk patient.

Other signs: Iris microabscess, absent red fundus reflex, retinal inflammatory infiltrates, and flame shaped retinal haemorrhages with or without white centres, corneal edema, eyelid edema, chemosis, conjunctival injection.

Chances of developing panophthalmitis and orbital involvement (proptosis, restricted ocular motility) are higher in these cases.

Differential diagnosis

1. Endogenous fungal endophthalmitis: may see fluffy, white vitreous opacities. Fungi grow on cultures.
2. Retinochoroidal infection e.g. toxoplasmosis and toxocariasis: yellow or white retinochoroidal lesion present.
3. Non-infectious posterior uveitis e.g. sarcoidosis, pars planitis may have a known history of uveitis. Unlikely to get coincidentally the first episode during sepsis.
4. Neoplastic conditions: reticulum cell carcinoma, usually older than 50-55years. Retinoblastoma, usually in the first few years of life.

Workup:

1. History: duration? Underlying infection or disease? i.v. drug abuse? Immunocompromised?
2. Complete ocular examination, including a dilated fundus examination
3. B-scan ultrasound to determine the extent of posterior segment ocular involvement if it cannot be determined on clinical examination.
4. Complete medical workup by an infectious disease expert.
5. Cultures: blood, urine, indwelling catheters, and i.v. lines with gram stain of any discharge. A lumbar puncture is indicated when meningeal signs are present.
6. Vitrectomy with intraocular antibiotics (e.g. amikacin 0.4mg in 0.1ml or ceftriaxone 2mg in 0.1ml; clindamycin 1mg in 0.1 ml. may be used in place of vancomycin). the timing of this procedure is controversial.

Treatment:

In conjunction with a medical internist.

1. Hospitalize the patient

2. Broad spectrum antibiotics: started after appropriate smears and cultures are obtained. Preferred route is parenteral with intensive and prolonged therapy.

Antibiotic choices vary according to the suspected source of the infection (gastrointestinal tract, genitourinary tract) and are determined by an infectious disease expert. Dosages recommended for meningitis and severe infections are used.

Antibiotics* used: broad spectrum antibiotics to cover gram-positive, gram-negative and anaerobic organisms are required

- a. Vancomycin 1g i.v. q 12 h or clindamycin, 300mg i.v. q 6 h

Plus

- b. Ceftriaxone 1 to 2 g i.v. q 12 h or gentamicin 5 mg/kg i.v. q 24 h
- c. Metronidazole 15mg/kg i.v. load, and then 7.5 mg/kg i.v., q 6 h when anaerobic infection is suspected.

**Antibiotics doses are reduced in renal disease. Peak and trough levels of vancomycin and gentamicin are monitored.*

BUN and creatinine levels are monitored closely.

Corticosteroids: should be given in high doses systemically in the posterior form of infection

3. Topical cycloplegics
4. Topical steroids
5. Periocular antibiotics
6. Role of intravitreal antibiotics: no role in anterior focal and diffuse form but can be given in posterior focal group if no bacterial isolate has been cultured. In the posterior group I/V injection of broad spectrum antibiotics has to be given early

Intravitreal antibiotics offer higher intraocular concentrations.

Doses :

- Vancomycin: 1mg/0.1ml
- Amikacin : 400microgram/0.1ml

- Ceftazidime: 2.25mg/0.1ml
- Clindamycin: 1mg/0.1ml

7. Vitrectomy: role is controversial but definitely indicated in posterior diffuse form of endogenous bacterial endophthalmitis. It has no role in anterior focal and diffuse and posterior focal group.

- Reduces infective load and Inflammatory debris
- Improves drug availability.
- Provides sufficient material for diagnostic culture and pathology.

To confirm the diagnosis lab investigations are must to culture the organism from both nonocular source and intraocular specimen.

Unlike in endogenous fungal endophthalmitis cultures are usually positive in bacterial endogenous endophthalmitis.

In some cases CT, x-ray and abdominal ultrasonography may be useful.

Prevention is the best option and predisposed patients should be evaluated periodically with a dilated fundus examination particularly if there is a history of blurring of vision, redness and photophobia.

Early diagnosis and prompt intensive systemic treatment may help in salvaging useful vision in some cases.

Endogenous fungal endophthalmitis

Etiology: MC cause is candida; considered as an important marker indicating its dissemination and colonization in several organs.

Candida is responsible for nearly 50-60% cases of the fungal endophthalmitis in different reported series followed by Aspergillosis at 24%.

Others are Histoplasmosis, Coccidioidomycosis, Cryptococcus, Fusarium, Blastomyces, Sporothrix and Mucormycosis.

Clinical features: Blurred vision, periocular swelling, pain (always less in comparison to signs).

Symptoms usually depend on the location of the fundus lesion.

Candidiasis: lesion is present in the retinal periphery so extensive disease may be present in the absence of symptoms.

Aspergillosis: lesion tends to involve the macula and is highly symptomatic.

Signs: anterior chamber reaction, vitreous inflammation, hypopyon, subretinal focal inner choroidal lesion, usually multifocal, gradually enlarges and breaks into vitreous cavity and appears as "cotton balls", perivascular lesion, focal intraretinal haemorrhages and retinal necrosis.

In filamentous fungi occlusion of choroidal and retinal vessels by invasion of fungal hyphae are also known to occur.

In endogenous endophthalmitis there is always a focus in the choroid or within the retinal layers, so parenteral antibiotics have a significant role in management.

Differential diagnosis:

1. CMV retinitis: minimal to mild vitreous reaction. More retinal hemorrhage, tend to concentrate along vessels, consider strongly in AIDS patients.
2. Toxoplasmosis: yellow white lesion confined to the retina. An adjacent chorioretinal scar may or may not be present. Vitreous cells and debris are common, But vitreous abscesses or cotton balls are not.
3. Others e.g. herpes simplex mycobacterium avium-intracellulare, nocardia, aspergillus and cryptococcus.

Workup

1. History: medications? Medical problems? Underlying infection or disease? i.v. drug abuse? Immunocompromised? Other risk factors for AIDS.
2. Search the skin for scars from i.v. drug injection.
3. Complete ocular examination, including a dilated fundus examination
4. B-scan ultrasound to determine the extent of posterior segment ocular involvement if it

cannot be determined on clinical examination.

5. Complete medical workup by an infectious disease expert.
6. Cultures: blood, urine, indwelling catheters, and i.v. lines for candida these often need to be repeated several times and may be negative despite ocular candidiasis.
7. Diagnostic and therapeutic vitrectomy: is indicated when a significant amount of vitreous involvement is present. Cultures and smears are taken at the time of vitrectomy to confirm the diagnosis and to evaluate the organisms sensitivity to antifungal agents.

Amphotericin B 5microgram in 0.1ml is injected in the central vitreous cavity at the conclusion of the procedure.

8. polymerase chain reaction: triplex and monoplex PCR are used for detection of fungal antigens and allow rapid identification of the causative organisms with high sensitivity and specificity even when the cultures are negative.
9. Baseline CBC , BUN, creatinine and LFT

Treatment

In conjunction with a medical internist.

1. Hospitalize all unreliable patients systemically ill patients or those with moderate to severe vitreous involvement.
2. An infectious disease specialist or internist familiar with antifungal therapy should be consulted.
3. Fluconazole 200 - 400 mg p.o. q.d.
4. Newer drug; Voriconazole (Vfend;Pfizer) is a new triazole with the broadest spectrum of antifungal activity.

Efficacy good against aspergillus, candida, fusarium, alternaria.

Dose

Oral 200mg b.d.

Topical 1% reconstituted solution every 4 hr.

Intravitreal dose 50 microgram/0.1ml

5. In resistant cases, amphotericin B may be used.for first few days 1 mg i.v. 5 times per day then larger doses totalling 20 mg/day are administered .
6. Therapy is discontinued when a total dose of 1000 mg has been given.
7. Topical cycloplegic agents
8. IOP control

Mainstay is early diagnosis and appropriate systemic and ocular treatment.

Ideally be managed in consultation with an internist.

most effective drug is Amphotericin B (potential toxicity including nephrotoxicity)

Azoles e.g. fluconazole,itraconazole,ketoconazole are fungistatic not cidal so resistance may develop during the course of treatment

Combination is not recommended as fluconazole decreases the efficacy of amphotercin B

Preferred route : systemic as most cases have non-ocular foci of fungal colonization,

Duration: several weeks to months

It takes a minimum of one week to detect any response unlike in bacterial endoph.

Corticosteroids by any route are contraindicated in early management.

Invasive procedures/surgical management: reserved only for patients not responding to intensive medical management

1. Employed as combined diagnostic and therapeutic modality
2. Specimen can be used for the etiological agent by microbiological tests and PCR.
3. Helps to clear the bulk of infective organism and inflammatory debris from the vitreous cavity.

Follow-up: antibiotic/antifungal regimen is guided by the culture and sensitivity results, as well as the patient's clinical response to treatment.

Traumatic & Childhood Endophthalmitis

Dr Raj Kumar Sharma, MS, FRF, FCLI Vitreoretinal Surgeon

Dr Sunil K Thakur, MS, Vitreoretinal Fellow

Sahai Eye Hospital and Research Centre

Traumatic Endophthalmitis

Trauma in the developing country is a major problem causing loss of several men hours with social and economic burden especially in labour class people where a single working man on daily wages is the only source of the income to his family, so injury to the eye becomes an important and preventable risk factor in those cases. Another important factor is the trauma in the children which is a major cause of childhood ocular morbidity/blindness.

Prevention is better than Cure

Condition constitutes an emergency and prompt action is required.

Symptoms:

Sudden onset of progressively decreasing vision, redness, and increasing eye pain.

Critical signs:

Signs of injury e.g. corneal/corneoscleral tear with or without RIOFB, hyphema

traumatic cataract, vitreous hemorrhage etc.

Intense flare and cell in the anterior chamber and vitreous, with or without hypopyon, eyelid edema, chemosis, and a reduced red reflex.

Patients with bacillus endophthalmitis may develop a high fever, Leukocytosis, proptosis, a corneal abscess in the form of a ring and rapid visual deterioration.

Organisms:

Bacillus species *S. epidermidis*, gram-negative species, fungi, Streptococcus, and others. A *mixed flora* may be present.

Differential diagnosis:

1. Sterile inflammatory response from a retained intraocular foreign body or blood in the vitreous.
2. Sterile inflammation as a result of surgical complications.

3. Phacoanaphylactic endophthalmitis

Workup:

1. History and examination: to know about the mode and duration of injury, type of foreign body.
2. B-scan ultrasound: to look for any RD, vitreous haemorrhage, RIOFB
3. X-ray to rule out retained intraocular metallic foreign body.
4. CT to rule out and to localize the RIOFB in selected cases.
5. Diagnostic and therapeutic vitrectomy: to get the vitreous sample for culture and sensitivity.
6. CBC with differential and serum electrolytes.

Treatment:

1. Hospitalization
2. Management for a ruptured globe or penetrating ocular injury if present
3. Topical fortified gentamicin/tobramycin and fortified cefazolin/vancomycin.
4. Subconjunctival antibiotics: benefit is limited and not often used if used may consider gentamicin and clindamycin which may be repeated.

Systemic antibiotics:

Vancomycin 1g i.v. q 12 h or clindamycin, 300mg i.v. q 6 h

And

Gentamicin 2mg/kg i.v. load followed by 1mg/kg i.v. q8h.

Or Cefazolin 500 to 1000 mg i.v. q8h.

Metronidazole 15mg/kg i.v. load, and then 7.5 mg/kg i.v., q 6 h when

Anaerobic infection is suspected.

5. Intravitreal antibiotics : amikacin or ceftazidime and vancomycin or clindamycin

Amikacin: 400microgram/0.1ml

Ceftazidime: 2.25mg/0.1ml

Vancomycin: 1mg/0.1ml

Clindamycin: 1mg/0.1ml

Can be repeated every 48 to 72 hrs, as needed.

6. Pars plana vitrectomy: to decrease the infective load, to remove the RIOFB, to repair the RD/to clear the vitreous hemorrhage if present.

7. Tetanus immunization: if not upto date, give tetanus toxoid 0.5 ml i.m.

8. Steroids: should NOT be used until fungal organisms are ruled out.

Posttraumatic endophthalmitis is different from other forms of endophthalmitis as

a. Trauma results in formation of a cocktail comprising a mixture of the damaged intraocular tissue with RIOFB, hemorrhage and infective organisms which makes the surgical management difficult and poor visual prognosis.

b. Disorganization of the normal anatomy due to trauma may cause difficulty in assessing the clinical features and in making an accurate diagnosis of endophthalmitis in early stages.

c. In these cases often the mixed flora are responsible for infection which require broad spectrum of antibiotics or combination of the two or more antibiotics to cover the entire organism.

d. The organism producing the infection is more virulent and has a high degree of pathogenicity.

e. The protocol for management remains ill-defined.

Trauma contributes to 17-40% of all cases of culture positive endophthalmitis.

Penetrating injuries with vegetable matter and retained intraocular foreign body are more likely

to produce traumatic endophthalmitis in comparison to the injuries with a sharp instruments with no RIOFB e.g. injury with a needle/compass etc.

Reported mean interval from injury to the onset of endophthalmitis:

1. Fulminant cases e.g. Bacillus cereus and streptococci about 1-2 days

2. Acute cases e.g. S.epidermidis and gram negative organisms about 3-4 days

3. Chronic endophthalmitis by fungi about 57 days.

Endophthalmitis due to B.cereus: infection is characterised by

1. history of trauma with a metallic foreign body lodged within the eye.

2. Severe orbital pain within 24 hrs of the injury and associated with a significant proptosis, chemosis and periorbital inflammation.

3. Corneal ring infiltrates and ring abscess

4. Constitutional symptoms

Treatment should not be delayed for want of diagnostic specimen.

B.cereus is resistant to cephalosporins.

Vancomycin, clindamycin, and gentamicin are effective against this organism.

Paediatric traumatic endophthalmitis:

One of the important causes of the childhood ocular morbidity is the ocular trauma, and it is different in several aspects from adult cases.

1. Lack of History: many times mode of injury and duration are not known.

2. Delay in presentation: due to lack of attention and unawareness of parents.

3. Difficulties in clinical assessment as children are uncooperative patients.

4. surgical difficulties : in children vitreous is solid/dense which leads to severe contraction and may result in ciliary body dialysis and choroidal detachment and complicated RD.

Chances of developing phthisis bulbi are higher in paediatric cases.


Use of silicon oil in paediatric cases may help in decreasing chances of phthisis bulbi as silicon oil acts as a tamponading agent and prevents the development and progression of traction

It also reduces the required effective doses of intravitreal antibiotics.

5. Even after successful anatomical recovery postoperative chances of developing amblyopia are also very high in children.

Overall prognosis in posttraumatic endophthalmitis cases has improved due to


1. Improvements in surgical techniques of wound closure
2. Better diagnostic facilities and early vitreous surgery
3. Availability of broad spectrum antibiotics
4. Improvements in the vitreous surgery and instrumentation.



SECTION 3

PREVENTION OF ENDOPHTHALMITIS

- | | | |
|---|-------------------|----|
| 1. How to Avoid Post Operative Endophthalmitis | Dr. Pavan Shorey | 45 |
| 2. Surgical Steps to Avoid Post Operative Endophthalmitis | Dr. Pankaj Sharma | 48 |
| 3. How to Avoid Post Operative Endophthalmitis in Eye Camps | Dr. Anshu Sahai | 51 |
| 4. Surgical Asepsis and Sterilization : CME series No. 4 (AIOS) | | 55 |



How to Avoid Post Operative Endophthalmitis

Dr. Pavan Shorey

Consultant Vitreo Retinal Surgeon, Jaipur Hospital

Prevention is better than cure, an old saying that holds true for endophthalmitis. Endophthalmitis is sight threatening which may make a patient blind inspite of our best efforts. This write up explains ways to reduce or eliminate the risk of endophthalmitis before, during or after surgery.

Preoperative preparations:

It is important to identify the risk factors for endophthalmitis. The ocular conditions are blepharitis, nasolacrimal doct infection and ocular prosthesis. The systemic factors are diabetes, immuno compromised patients, active infection elsewhere in the body (Table 1).

TABLE 1

Risk Factors for Endophthalmitis

Patient factors:

1. Ocular conditions
 - a. Bacterial blephritis
 - b. NLD infection
 - c. Ocular prosthesis
2. Systemic conditions
 - a. Active conditions
 - b. Diabetes
 - c. Immune compromised patient

Surgical factors

- IOLs with prolene haptics
- Posterior capsule tear
- Vitreous loss
- Clear cornea incisions
- Contaminated BSS, IOL

Preoperative examination

Most cases of endophthalmitis are caused by patient's own ocular flora: Staph. Epidermis, Staph. Aureus, and the streptococci specis.

Preoperative examination should rule out any sign of local infection: Blepharitis, conjunctivitis or chronic daryocystis and appropriate measures should be taken to treat them.

- **Lacrimal obstruction:** Tends to be colonized by pneumococcal bacteria, hence lacrimal sac surgery needs to be done prior to cataract surgery.
- **Should a conjunctival swab for culture sensitivity be routinely be done?** If there are no signs of any infection there is no need to do so. But this should be considered in one eyed patients, in patients with prosthetic other eye, patient who have had endophthalmitis in one eye, patients with retinal detachment surgery who have had a buckle infection, vitreoretinal surgery and patients who are treated for any of the risk factors mentioned previously. Diabetes per se is not an indication.

Patient on previous artificial tears, glaucoma drops:

Examine the eye for any signs of infection. Insist on patient switching to a fresh bottle of drops at least a week before surgery.

Preoperative antibiotics

A topical antibiotic (ofloxacin or moxifloxacin) four times a day 3 days before surgery is sufficient.

Studies have shown that patient who have a combination of preoperative antibiotics 3 days before surgery + antibiotic drops and povidine iodine drops on day of surgery had only a 19% positive cultures before surgery ; the other group which received topical antibiotics and povidine iodine drops on the day of surgery had a 42% positive cultures before surgery.

On the day of surgery

- After receiving preoperative antibiotic drops for 3 days prior to surgery.
- 3 more doses of antibiotics drops 1 hour before surgery.
- Dilating drops can be instilled after or along with antibiotic drops.
- Periorbital area is painted with povidine iodine (Betadine 5%) and left for 2 minutes

- Povidine iodine is instilled in the conjunctiva in 2 forms
- Drops - 2 drops for 2-3 minutes
- Irrigating the conjunctival surface with large volume of povidine iodine using syringe attached to a cannula, surgeons can flush 10 cc of povidine iodine in the conjunctival fornices (Studies have shown that patient who had irrigation with povidine iodine had much less positive conjunctival cultures (26%) compared to the group with drops only (42) prior to surgery).

Antibiotics and povidine iodine are an effective combination for reducing bacterial count as they have a synergistic effects.

Surgical site is painted and opsite applied: the following method should be adopted -

Paint the periocular region with Povidone-Iodine 5% (betadine) solution. The horizontal extent must be from midline to the beginning of auricle and the vertical extent from the hair line to a line passing horizontally from angle of mouth. Wait for it to dry for about 2 mins. Scrub lid margin with betadine applicators. Instill betadine drops into the cul de sac. Wash after 2 min with normal saline. Again paint the above mentioned region and let the region dry.

Apply Opsite or other similar adhesive taking particular attention to ensure its tight adherence at the medial canthus, nasal bridge and nasolabial fold. Keep the adhesive slightly redundant over the open eyelids while applying. However prevent corneal touch. Lift the temporal edge of adhesive at the lateral canthus and make a horizontal slit upto the medial canthus. At the medial canthus cut in a V or T pattern. Insert the eyelid speculum in such a manner that the eyelid margin and eyelashes are wrapped within the edges of the adhesive.

During surgery

The four primary intraoperative issues that can impact a patient's risk of endophthalmitis are wound leaks, posterior capsule rupture, phaco burns, vitreous loss

Wound Leak:

A leaky wound is a sign of poor closure

postoperatively. When the IOP decreases the posterior lip of the wound opens up allowing ingress of bacteria of the conjunctiva. If the wound is leaking it is advisable to apply a suture after surgery.

Posterior Capsule Rupture (PCR):

A posterior capsule rupture exposes the eye to infection. To avoid this catastrophe one must:

- Perform through hydrodelineation to separate the cortex from the capsule and lessen the risk of PCT
- Avoid using high vacuum settings when working near the capsule.
- SICS: Avoid in small pupils, good viscoelastic between the posterior capsule and nucleus before nucleus expression, anterior chamber should be maintained throughout surgery.

Phaco Burns:

A wound burn can affect the healing of the incision, risking infection

- Incisions smaller than 3 mm can be prone to friction from motion of phaco needle as well as heat transferred from compression of silicone sleeve.
- Remember the first sign of an impending phaco burn is the appearance of "Lens Milk" stagnating at the phaco tip. If you detect this, stop your phaco and fix the problem.

Vitreous Loss

Is an important risk factor for endophthalmitis because it is in itself a good media for bacterial growth. If vitreous is incarcerated in the wound it can imbibe the bacterial and act as a gateway for infection.

- Thoroughly clean the vitreous from the wound and perform a good anterior vitrectomy.

Intracameral antibiotics

3 antibiotics have been used

- Vancomycin
- Moxifloxacin
- Cefuroxime

1. **Intracameral cefuroxime:** Given as a dose of 1 mg in 0.1ml intracamerally at the end of the surgery. The ESCRS study on

endophthalmitis showed that there was a 5 fold decrease in the incidence of endophthalmitis as compared to the group that did not receive (incidence 0.05% compared to 0.3% in the control group) the intracameral injection.

There are issues about the preparation of the drug from a 750mg vial and it is not widely followed in India.

- 2. Intracameral vancomycin or vancomycin in the irrigating fluid.** Inj. Vancomycin is widely used in the irrigating fluid and anecdotal reports have reported a decrease in the bacterial load in the aqueous.

Vancomycin injected in the anterior chamber has a half life of 2 hours but vancomycin needs several hours to have bactericidal effect, besides this is the problem of antibiotic resistance. Vancomycin is the best agent for use against gram positive organisms. In 1995, Centers for Disease Control and Prevention, USA issued a warning that vancomycin should not be used as prophylaxis. However to use it: 10 ml of ringer lactate is injected in vial of 500mg of vancomycin. 0.2ml of vancomycin is injected in 500 ml of BSS.

- 3. Intra cameral moxifloxacin:** Some surgeons in India use preservative free moxifloxacin drops which they inject directly intracamerally (dose 0.1ml drawn directly with aseptic precautions into a 1 cc syringe and injected in the capsular bag. Reports are anecdotal, there is no proven evidence to suggest that this prevents endophthalmitis.

The use of intra cameral antibiotics just after surgery is shrouded in controversy. Each surgeon should read what literature has to offer and decide for himself.

Just after surgery:

- A drop of moxifloxacin or gatifloxacin
- Systemic antibiotics is a personal choice. Tab ciprofloxacin 750mg OD, Tab. Gatifloxacin 400mg OD or ofloxacin 400mg OD give sufficient concentration of the drug in the eye.
- Antibiotic - steroid combination drops are given four to six times a day.

The issue of phaco hand piece and sleeve.

It has been seen that the same phaco handpiece and sleeve is used to operate a number of cases at a time. Personal experience is cited that no endophthalmitis is encountered when using a phaco probe sleeve multiple times on the same operating day. This may be true but it is also true that such practices can lead to cluster endophthalmitis if there is some lacunae in sterilization. Ideally, there should be 2 phaco handpieces sleeves should be changed with every case and phaco handpieces flash sterilized for each case.

TABLE 2 :

ESCRS Endophthalmitis Study

Aim: Do perioperative antibiotics prevent endophthalmitis. How should the antibiotics be administered: Intracameral injection or intensive topical drops or both.

Study Design: 15971 subjects were enrolled from 23 clinics in Europe

- Half of the patients were assigned to receive 1 mg of intracameral cefuroxime in 0.1ml of normal saline at the end of surgery
- Half of the patients were the control group who received povidine iodine + topical levofloxacin like the other group.

Results: The group receiving intracameral cefuroxime had a 5 times less incidence compared to the control group (6 per 10,000 versus 33 per 10,000 cases).

Risk Factors: Use of silicone instead of acrylic IOL, clear corneal incision as compared to a scleral incision.

The effect of intracameral cefuroxime: ESCRS study proved that this method decreased the incidence of endophthalmitis by five times (0.05 compared to 0.3% in the control group).

Why Cefuroxime: It is effective against a majority of organisms that cause post operative endophthalmitis.

Surgical Steps to Avoid Post Operative Endophthalmitis

Dr. Pankaj Sharma

Associate Professor, Ophthalmology

The past decade has seen unprecedented advances in eye care. Today, we as ophthalmologists, can offer a much better prospects to our patients. It is ironical that endophthalmitis is one area which has shown an increase in this period. Post-cataract endophthalmitis is on the rise and Clear Corneal Incisions (CCI) are implicated. This does not, however, mean that this technique should be abandoned. CCI was first described by Howard Fine in 1992 but was popularized not earlier than 2000.

There are many studies which have supported this belief.

First, a 2005 review article by Taban and colleagues in the Archives of Ophthalmology compared the years 1963-2000 with the years 2000-2003 and revealed a 2.5 fold increase in endophthalmitis. About half of the US surgeons switched to CCI by 2000, according to ASCRS survey.

Second, a 2005 review article of the 1994-2001 Medicare database by West and colleagues found a significant increase in cases from the years 1994-1997 to the years 1998-2001.

Finally, the ESCRS Endophthalmitis Study of nearly 16,000 cataract patients revealed that those with CCIs were nearly six times more likely to get endophthalmitis than those with sclera tunnel incisions.

The mechanical stability of the CCI is dynamic, and varies as a function of intraoperative pressure during the postoperative period. As the intraoperative pressure comes down over the postoperative period, before any substantial wound healing can occur, there may be gaping along the internal and even external aspect of the incision. This gaping may allow bacteria or other

matter to enter the anterior chamber of the eye. How mechanical pressure affects CCIs was shown in a 2004 study in the *American Journal of Ophthalmology*. In the study, India ink was applied to the corneal surface of seven fresh human donor globes that had undergone clear corneal surgery. Applying pressure to the surface of the eye allowed the ink to gain access to the anterior chamber in four of the eyes. A 2005 study by Herretes and colleagues in the *American Journal of Ophthalmology* found that blood-tinged tear fluid entered the eye in all eight patients studied, and a 2003 case report by Aralikatti and colleagues in the *Journal of Cataract and Refractive Surgery* revealed that ointment also can enter the anterior chamber.

Because of this ability of surface fluid and even ointment to traverse CCIs and reach the anterior chamber in some eyes, perhaps aided by transient low intraocular pressure, Dr McDonnell has proposed "new strategies" be used in the early postoperative period.

Don't Throw the Baby Out ...

Though the implication is irrefutable, not all surgeons have reported an increase in the endophthalmitis rate. Dr. Howard Fine has reported an 11 year endophthalmitis-free period in over 10,000 cases in clinical practice. Likewise, John Hunkeler, MD, Clinical Professor, University of Kansas, USA, reported the same 10 year endophthalmitis-free period in his 10,000 cases.

Since the benefits of CCI are also irrefutable, one needs to change the strategies for the same.

1. Incision construction and architecture
2. Use of intracameral antibiotics
3. Use of pre-op topical antiobiotics and Povidone-iodine 5% in conjunctival sac

4. Wound sealing with stromal hydration
5. Use of suture for gaping wounds
6. Leaving the eye unpatched with early institution of topical antibiotics.

The Incision

In a landmark study, Fine et al published findings in 2007 issue of JCRS, profiling CCI in living eye tissue using Optical Coherence Tomography (OCT). The study concluded that proper clear corneal incision construction resulted in a markedly more stable and safer incision architecture.

Dr. Fine's research found that the incision is not the straight, flat plane, as has often been drawn. Instead he and his co-investigators found cataract wounds are very much arcuate incisions, like tongue and groove paneling. It was also reported that it much longer than the cord length of the incision, forming a sort of hyper-square. Another important finding that emerged was that the effect of stromal hydration lasts much longer than previously thought (even longer than 24 hours).

Thus it is suggested that the blade should be aimed in the plane of the cornea (not perpendicular to it) and going uphill until the cord length is 2 mm, and then entering the Descemet's membrane (Fig. 3). This approach gives the best arcuate construction (Fig. 2). A trapezoidal blade is better since it allows further enlargement of the incision by simple advancement of the blade, rather than a to-and-fro movement. Blades with preset markings (Fig. 1) are helpful to titrate the exact length and width of the incision. CCI should not be enlarged beyond 2.6 mm (Fig. 2). With refinements in IOL design and injector systems, this limit is almost never crossed. However, too much stretching of a small incision can lead to a much more unstable incision than a larger, but, properly configured wound.

Side-Port incision

The construction of the side-port incision should follow the same principles as the primary incision with direction in the corneal plane. These incisions have been observed to leak more

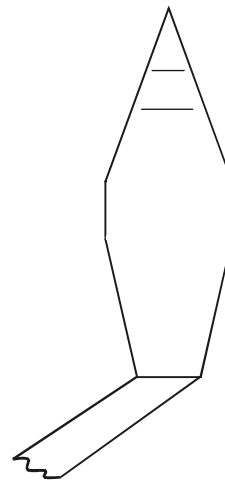


Fig.1 Blade with preset markings

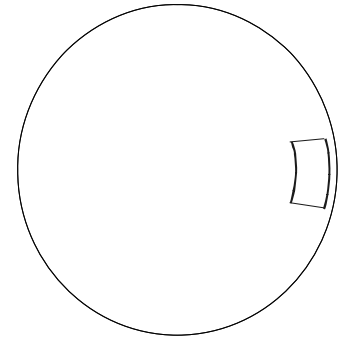


Fig.2 Ideal Trapezoidal configuration of 2.6mm CCI

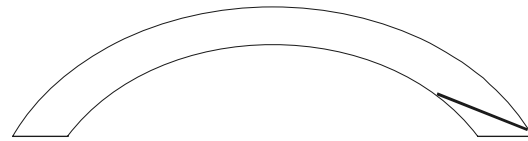


Fig.3 Plane of Clear Corneal Incision

commonly than the main incision. As this port is commonly used to stabilize the globe, care should be taken not to distort it. Fixation ring is a better option for globe stabilization.

Since right-handed phaco-surgeons make a 6 o'clock side port incision in left eyes, these eyes have been reported to be at an increased risk of endophthalmitis. Also, the sideport incision used in bimanual microincision surgery remains a significant risk factor for endophthalmitis as it is often seen to fishmouth at the end of surgery and can be difficult to seal.

Intracameral Antibiotics

Intracameral vancomycin and cefuroxime have been widely used for antibiotic prophylaxis with very gratifying results. However, they have to be titrated in the OR on a daily basis, increasing the risk of improper dose administration. Intracameral moxifloxacin has also been reported with equal efficacy and has been used in titrations from full strength to 1:5.

Preop Antibiotic Regimen and Intraop Povidone Iodine

Pre-op loading patients with fourth generation quinolones 2-3 days prior to surgery significantly reduces the bacterial load. Careful preparation of the surgical field with isolation and turning away of the eyelashes with the surgical drape followed by application of 5% povidone iodine to the conjunctival sac kills transient microbes on the surface.

Stromal Hydration

It cannot be over-emphasized that each wound should be checked for leakage immediately post-op. Stromal hydration of all four walls of the main and side-port incisions helps to achieve adequate sealing for more than 24 hours, as shown by Dr Fine. Vasavada et al (2007) also published a report in JCRS, proving that stromal hydration significantly reduces the ingress of trypan blue

into the anterior chamber from the conjunctival sac. Thus this step may have a beneficial effect in reducing the risk of endophthalmitis.

Dr Fine, routinely documents wound sealing with fluorescein sodium 2 % dye at the end of the procedure.

Needless to say, one should not hesitate to suture a leaking wound.

Patients operated under topical anaesthesia should preferably be left unpatched with early institution of topical antibiotics. Any type of wound compression or hypotony should be avoided in the immediate postop period.

Cataract surgery is not a race for smaller incision. It is all about being able to conduct perfect cataract surgery through an astigmatic free, small incision with a sound wound integrity at the end of the procedure.

How to Avoid Postoperative Endophthalmitis in Eye Camps

Dr. Anshu Sahai*, Dr. Gyanendra Singh**

Despite numerous advances in the field of ophthalmology cataract still remains the leading cause of avoidable blindness throughout the world. Operative eye camps in the remote areas have served a great purpose by reducing this backlog to a great extent. Though time and again people have raised doubts about the quality of services provided in such camps, commendable success rates can be achieved if the case selection is proper, surgery is done in adequate conditions and post op care and follow up is meticulously undertaken. Endophthalmitis specially cluster endophthalmitis remains a serious issue and the people against eye camps make a case about lack of ideal OT conditions in such situations. How does one prevent endophthalmitis in eye camps? Based on our experience and the recommendations of national programme of prevention of blindness¹ we suggest the following measures be taken to prevent endophthalmitis.

Site Selection

The doctor- in - charge of the camp should be aware of the proposed camp site well in advance. A visit by the doctor or some senior experienced paramedical staff to the camp site, preferably a week before the camp day, is absolutely essential. Before approving the site following points are to be taken into consideration.

1. A running O.T. (PHC/ Pvt. Hospital) is always preferred as it provides the surgical team with near ideal conditions to operate as well as minimising the chances of infection.
2. In case the camp is being planned in some other building (school, dharamshala) it should be ensured that the camp operation theatre should be set up in a room spacious enough to accommodate the instruments and the surgical team comfortably.

3. The room should be secluded, located away from the crowded part of building preferably on first/second floor and well sheltered. Lesser crowds around OT play an important part in minimising the chances of infection.
4. An enquiry should be made about the purpose for which the room was being used. Reject if the room was being used as a kitchen, cattle shed, store room for food grains or was not in use for a period of more than one month as all these factors can lead to the room having potential sources of infection which are not destroyed by routine methods of disinfection.
5. The room should preferably have minimum windows, a single door, no taps or drains. Air conditioners, if not present, should be installed.
6. The room should have adequate lighting arrangements in the form of bulbs & tube lights as well as power points thus keeping the room relatively free of wires, extension cables and other lighting sources.
7. Once the room is approved the person in charge of that room should be given proper instructions about cleaning the room daily till the day of camp. Author personally recommends twice daily cleaning of the room including walls & ceiling along with a wet mopping of the floor with available disinfectant like phenyl for at least a week before the camp.
8. Apart from the time of cleaning the room should be kept locked always.

Preparation at the Base Hospital

At the base hospital preparations for the camp should commence at least two weeks in advance. Author recommends constituting a team

* Director & Ophthalmologist, Sahai Hospital & Research Centre, Jaipur

** Resident Doctor (DNB), Sahai Hospital & Research Centre, Jaipur

including senior doctors as well as paramedical staff for the camp to form an 'Infection Committee'. The team should concentrate on the following points while preparing for the camp.

1. A target regarding the estimated number of surgeries should be kept in mind.
2. Preparations should be made for at least one and half times the proposed number of surgeries.
3. All the consumables should be stocked well in advance. Author recommends using the tested brands only, be it consumables or the instruments. Using a new product in such camps is strongly discouraged as one can't be sure of the quality of a new product.
4. All the consumables should be double checked for expiry date, any breakage in the packaging, any visible contamination of the solutions, and any damage to the instruments before sending them for autoclave.
5. Author strongly disapproves of any local procurement of even a single needle to be used per operatively or post operatively as any weak link in the chain of sterility can lead to calamitous results.
6. Once the check list is complete the items requiring autoclaving are sorted out. All of these are autoclaved a day before the planned surgeries so that the sterility is maintained. No item is to be used 48 hours after it has been autoclaved. A portable autoclave can be transported to the camp site in case the need arises to autoclave during the camp. The choice of method & type of autoclave is a matter of personal preference.
7. All fluids & liquids used per op, which are thermo stable, including BSS, RL, Xylocaine etc. should be autoclaved.

Preparing the Operation Theatre

THE first thing to do on reaching the camp site is to take over the camp operation theatre. It is then prepared for the next day.

1. Make sure no unauthorised person (including the local volunteers) enters it

even during preparation.

2. Dusting of fans, lights, windows, ceiling and walls is undertaken. If available a vaccum cleaner is the best option.
3. A thorough cleaning of the room including washing the floor with water mixed with a good quality disinfectant like phenyl is to be undertaken before placing any of the instruments inside it.
4. It is advisable to unpack the O.T. goods inside the room only.
5. The instruments and tables are put into position taking care to keep the level of furniture the same as that of operating table as it helps in maintaining the level of sterility.
6. Any extra furniture required is to be brought in before going for fumigation.
7. Windows and any other exhaust openings are to be double packed i.e. from inside as well as outside using water proof material and a good quality adhesive.
8. If possible the arrangement for giving the blocks should be made inside the O.T. only.
9. Door is closed using double curtains so as to create an air lock and a cross entry system.
10. Once everything is in place a wet mopping of floor as well as furniture with a good disinfectant is to be done.
11. Now fumigation is to be undertaken. It can be done using formalin vapours (30 ml of 40% formalin dissolved in 90 ml of clean water for a space of 1000 cubic feet). The room is then closed for 6 hours. Carbolisation is then undertaken with 2% carbolic acid. However the main disadvantage of this method is that it takes 24hours for the pungent smell of formalin and carbolic acid to dissipate.
12. Potassium permanganate (10gm) can be mixed with 35 ml of 40% formalin in a basin (in case fumigator is not available) for a space of 1000 cubic feet. This method apart from being time consuming (minimum

contact period of 36 hours), has other shortcomings in the form of KMnO_4 being a carcinogenic compound and its pungent fumes can lead to serious breathing problems among the old aged patients. Personally the author does not prefer both these methods.

13. Another new method is to use 'aldekol' which contains a mixture of 6% Formaldehyde, 6% Glutaraldehyde, and 5% Benzalkonium Chloride. (325 ml mixed with 150 ml of water and sprayed by aerosol for 30 minutes. The room is then closed for 3 hours (if possible then closing overnight is best).
14. Author uses either Bacilloid (containing chemically bound formaldehyde, glutaraldehyde, and Benzalkonium Chloride) or Mikrobac forte(containing Benzalkonium Chloride and Dodecyl bis propylene triamine) - 80 ml mixed with one litre of water for 1000 cubic feet for a contact period of minimum 6 hours.
15. Silvicide, a newer agent containing silver nitrate (0.01%) and hydrogen peroxide (10%) can also be used in concentration of 20% as its fumes are non irritating.
16. The use of Aldekol, Bacilloid, or Microbac requires the use of a 'fogger'. The author prefers to use these 3 by rotation.
17. The room is to be locked by the senior person in team and under no circumstances it is to be opened before the scheduled time or by any unauthorised person.

Conducting the Surgeries

The room is opened half an hour before the scheduled O.T. All the instruments and furniture are checked again. Windows are examined for any defect in packing.

1. Arrangements for scrubbing are to be made adjacent to the OT room.
2. Surgeons and assistants have to don autoclaved gowns over the OT dress as well as masks, caps and OT footwear. Masks should completely cover the nose and mouth & fit snugly against the face. Masks should not be left dangling under the chin.

3. Gloves are to be worn by surgeons as well as assistants. Operating with bare hands is to be discouraged strongly.
4. Ideally one set of instruments are to be used for one case only. However if this is not feasible then it is recommended that either a flash autoclave is used or the instruments are thoroughly cleaned and soaked in acetone for a minimum of 30 minutes before they can be reused. If possible using disposable instruments is also a good option.
5. Number of paramedics inside the OT is kept to as minimum as possible.
6. Instrument trolley is to be prepared by the concerned person only after scrubbing (not by an unscrubbed person using chittle forceps).
7. Instillation of antibiotic drops (Ciprofloxacin/Tobramycin) 3-4 times minimum before the surgery starting from the time of admission is recommended.
8. If possible, the patients are provided with gowns before entering the O T.
9. Trimming of eyelashes is a good practice which can help in preventing infection (though some surgeons may not agree). It should be undertaken before the patient comes in OT for blocks.
10. Opsite or similar other adhesive should be used taking particular care to ensure its tight adherence at the medial canthus, nasal bridge and naso-labial fold.
11. Povidone - Iodine (5%) is to instilled for 2-3 minutes in the conjunctival sac before initiating the surgery or even before giving block as patients own conjunctival flora has been proved to be the main source of infection.
12. Use of antibiotics in irrigation fluid (Vancomycin 10 mg/500ml, or Gentamicin 4 mg /500ml) despite being a debatable issue in preventing infection is still recommended by the author.
13. Subconjunctival antibiotics at the end of surgery are to be practised religiously without fail.

14. All during the surgeries OT atticates are to be strictly enforced with a unsterile (unscrubbed) person not entering the sterile area i.e. around the trolley and the operating end of tables and maintaining a minimum distance of 12 inches from the sterile items.
15. If there is any doubt about the sterility of any item then that item is considered as unsterile.
16. Author strongly disapproves of any person other than surgical team entering the OT during surgeries.
17. The soiled linen which includes eye towels, discarded gowns and gloves are to be kept in dust bins away from the operating field.
18. Apart from the above mentioned measures the operating surgeons have to maintain the highest possible standards of asepsis during the surgeries so as to set an example for the subordinates.
19. The doctors in the outdoor have an equally important role in preventing infections as they have to carefully screen the patients for surgery with a strict denial of admission to the patients having local or systemic infections. (Author strongly recommends that only qualified ophthalmologists/resident doctors should screen and admit the patients)

Post Operative Care

With all the hard work done, it is not a time to relax as a meticulous post op care is absolutely vital for the final outcome of the surgical endeavour.

1. A team comprising of at least one qualified ophthalmologist along with trained paramedics has to remain at the camp site for a minimum of 2 days after the surgery to

do post op dressings as well as to look out for any complications.

2. Again as with the OT author advocates using tested consumables for post op dressings. The autoclaved cotton swabs are to be used by a trained paramedic after a thorough scrubbing. The solutions (povidone-iodine/savlon) are to be brought in advance from the base hospital. No local procurement is advised.
3. Eye drops (antibiotic –steroids, cycloplegics) are to be put by the medical staff maintaining aseptic conditions and not by the patients attendants (whose number and visits to the post op ward should be kept as minimum as possible)
4. A thorough and careful examination of post op patients should be made. Author favours the use of portable slit lamp to detect any abnormal reaction in suspected cases. Such cases are to be managed aggressively with early intravitreal antibiotics and/or steroids, and if required vitrectomy. They should be shifted to base hospital without any delay if the need arises.
5. Proper instructions have to be given to the patients about post op care. Symptoms of endophthalmitis should be informed to all patients on discharge (i.e. a minimum of 48 hours after surgery), with a strong recommendation to report to the base hospital for further management in the slightest doubt of endophthalmitis.

To conclude, operative eye camps are a need of hour for a country like ours but one has to take utmost care and precautions while arranging such events as however noble might be the intentions any mishap in such events can prove disastrous not only for the patients but for the surgeon also especially in this media savvy country.

References

1. NPCB-INDIA Newsletter (Vol. 1, No. 4 – January – March 2003)
2. AIOS – CME series – 4-Prevention of Endophthalmitis, Dr. Lalit Verma, Dr. H.K. Tiwari, Dr. Pradeep Venkatesh.
3. Author's own vast experience in conducting operative eye camps (over 500 camps conducted during past two decades)

Surgical Asepsis and Sterilization

Excerpted from CME series (4) (AIOS) on endophthalmitis with kind permission of Dr. Lalit Verma, Hony. Gen. Secy., AIOS

Strict asepsis is a hallmark of all modern day surgery. Even in this era of potent antibiotics, asepsis and sterile surgical technique remain the pillars for protecting the patient and for rendering the most satisfactory result from surgical intervention.

Although commonly used interchangeably, the terms 'aseptic technique' and 'sterile technique' have different connotations. Asepsis means absence of sepsis (infection). Aseptic technique is constituted by the series of practices employed to prepare the environment, the personnel and the patient, since it is near impossible to sterilize these. Practices employed to prepare the instruments, supplies and other inanimate objects used during surgery are designated as 'sterile technique'. The former decreases or abolishes the pathogenic load while the latter clears all living organisms in both the vegetative and spore state.

Aseptic Technique

- * Practices employed to prepare
 - Environment
 - Personnel
 - Patient
- * Renders above free of pathogenic organisms

Sterilization Technique

- * Practices employed to prepare
 - Instruments
 - Supplies
 - Other inanimate objects
- * Renders above free of all living organisms, both vegetative or spore form.

Principles of aseptic technique

The basic principles that dictate the choice of procedures employed in the operating room concerns one of four sources of contamination :

environment, personnel, patient and instruments and supplies:

Sources of Contamination:

Environment related factors are concerned with the location of the operating room, its water and air supply, traffic patterns, house keeping practices, laundry processing and refuse disposal. Factors related to the surgical team and personnel concern personal hygiene, dress code, movement, skin contaminants and team activity. Patient related factors include general health, preoperative preparation, transportation to the operating room and preparation of the surgical site.

The Environment: Asepsis of the operating room

The operation room is so planned that it keeps the flow of traffic from clean areas to dirty ones and never vice versa, prevents cross contamination and allows maximal environment sanitation.

The operation room is most often located in a blind wing or on the top or bottom floor. This is because such a location enables easier traffic control and allows the air and water supply to be more easily separated from the rest of the hospital. In the past, operating rooms were situated from high up in the hospital building to avoid contamination from dust in the air. Presently however, the development of controlled air circulation systems have obviated this need. Since the major sources of air contamination in the operation room are the surgical team and patient, no amount of carbolic mist will ensure aseptic air during surgery. Thus it is now emphasized that air in the operating room should so circulate that it prevents deposition of these dust particles. A laminar air flow system helps to achieve this objective. In this system, outside air is first filtered and then circulated after cooling

and moisturizing it to achieve the needed humidity. Sufficient air pressure needs to be maintained to prevent a suction effect. The recommended number of air exchanges is 15-25 every hour, with the optimum being about 16 times.

Every location meant for surgery should have two regions, a restricted and an unrestricted area. The restricted area is subdivided into a sterile area and a substerile area. The restricted area houses the operating room, sterile supplies, the instrument collection and processing area, autoclaves, anaesthesia supply area and entrance to the post-anaesthesia recovery room. The substerile area is a partially enclosed area, adjacent to an entrance to the operating room, where the autoclave and often a utility counter is located. It is effectively an extension of the operating room since the sterile gowned scrub nurse is often required to retrieve sterile instruments from the autoclave. It is hazardous to have the scrub sinks located in the substerile area particularly if there is no adequate barrier between the sink and the autoclave area. Offices, posting office, lounges, entrance to dressing rooms, sterile storage areas and patient transfer areas should be located in the unrestricted area.

Housekeeping is an important factor for ensuring proper asepsis in the operating room. This involves care of walls, ceilings, floor, vents, light fixtures, shelves, furniture and sink areas. Ideally the floor should be sprayed and wet vacuum pickup used between surgical procedures and at the end of the day. An alternate but a less effective method would be to mop (with a clean head every time) using a two bucket system.

Spot cleaning of walls and the ceiling should be undertaken as needed every day. Doors and switches should be cleaned with a germicidal detergent. Open shelves need to be cleaned daily with a detergent while closed cabinets may be cleaned once weekly.

The sink area should be cleaned several times daily and kept as dry as possible. The spray heads

on the faucets should be removed and cleaned daily.

The outside of autoclaves should be cleaned daily while the inside surface is cleaned weekly. The inside cleaning needs use of trisodium phosphate to remove the chemical residue.

Furniture used during a surgical procedure needs to be wiped with a detergent - germicide at the end of each case and cleaned thoroughly at the end of the day. The same applies to spotlights and other portable equipment, stretchers and kickbuckets. The latter in addition should be steam cleaned weekly.

Before removing her gloves, the scrub nurse should place all soiled linen inside the laundry bin. No one should handle soiled linen inside with bare hands. Soiled linen should also never be left on the floor or transported on a trolley used for other purposes. The laundry bin should be removed immediately after it fills up.

Liquid waste materials such as the contents of the suction bottle should never be disposed of in a scrub sink or utility sink but only into a container meant for the purpose. Ideally however, disposable suction bottles should be used. Glass suction bottles when used should be cleaned with a disinfectant and autoclaves before reuse. If autoclaving is not possible, they should at least be cleaned with disinfectant between cases.

Operation theatre sterilization

The routine method consists of washing the theatre with copious amounts of water. This is followed by fumigation with formalin vapour (30 ml of 40% formalin dissolved in 90 ml of clean water for fumigation of 1000 cubic feet by aerosol spray). The room is kept closed for 6 hours. Carbolisation with 2% carbolic acid is then undertaken. This method has the disadvantage that it takes about 24 hours for the pungent smell of formalin and carbolic acid to dissipate. If fumigator (oticare) is not available use 35 ml of 40% formalin with 10gms of potassium permanganate ($KMnO_4$) in a basin for a space of 1000 cu. Ft. and seal for 24 hours.

A new method of fumigation has been evolved using 'Aldekol', a mixture containing 6% formaldehyde, 6% glutaraldehyde and 5% benzalkonium chloride. To sterilize 4000 cu ft., 325 ml of aldekol is dissolved in 150 ml of water and sprayed by aerosol for 30 minutes. The room is then closed for 2 hours following which fumes are allowed to clear by putting on the exhaust or airconditioning. In effect, the operation theatre is sterile in just over 3 hours.

Personnel and operation room aspects

As they cannot be sterilized, disinfected or contained, personnel remain the greatest source of contamination. Unco-operative and inappropriate behaviour compounds the risk.

General health and personal hygiene of individuals working in the operating room needs close monitoring. Those with upper respiratory tract infections, draining skin lesions, or infections of the eyes, ear or mouth should not be permitted on duty.

Dress code has to be strictly enforced. All personnel must change into hospital laundered scrub attire and don disposable shoe covers, a disposable head covering that adequately covers all scalp hair and a properly tied high filtration (at least 95%) face mask before entering the operating room. Everyone in the operating room should wear scrub apparel with long sleeves and tight cuffs at the wrist. Face masks should completely cover the nose and mouth and fit snugly against the face. There should be no venting on the cheeks. Masks should not be left as a simple, inexpensive means of reducing cross contamination. They should be removed when leaving the restricted area.

Surgical Scrubbing

The objectives of the surgical scrub are to remove dirt, skin oil, and as many micro-organisms as possible from the hands and arms and to inhibit the growth and reproduction of bacteria on the skin for as long as possible. Skin of the hands must be free from cuts and abrasions; nails must be short and free of nail polish.

There is no consensus on the best method of scrubbing, the most effective antimicrobial solution, the adequate duration of scrubbing time and most effective means of applying friction to the skin. Both the timed anatomical scrub (3-10 minutes) and counted brush method are considered satisfactory. Surgical scrubs containing polyvinyl pyrolidone - iodine (PVP - iodine) are considered most effective.

Method of scrubbing: Wash hands and arms to two inches above the elbow and clean fingernails under running water. Wet scrub brush and apply antimicrobial soap solution if the brush is not already impregnated. Begin scrubbing palm, outer and inner aspect of each finger, the fingernails, the dorsum of the hand and circumferentially work up to the elbow. Rinse the hand and arm, keeping the arm above elbow level.

If one touches anything in the process of scrubbing, the procedure should be repeated.

Gowning and Gloving

In order to minimize the risk of contaminating the sterile operative set up during the process of gowning and gloving a separate table should be used. Only the scrub nurse should gown and glove herself, the rest should avoid self gowning and gloving. This minimizes the risk of contamination from dripping water on the sterile table in the process of picking up the hand towel and self gowning.

Members of the team should be gowned and gloved as soon as they enter the room. Once gowned and gloved, they should remain in the sterile end of the room until the patient is draped and the sterile set up is moved into place.

During any waiting period, the sterile gowned and gloved members of the team must keep their hands at waist level in front of them during this time. They should never sit, place their hands on their lap, or fold their hands.

Once the gown is donned, several areas are considered contaminated. These are neck and two inches below, edges of the cuffs and below the waist. If a wraparound gown is not worn, the entire back is also considered unsterile.

Supplies, instruments and equipment creating a sterile field

The furniture on which the sterile packs are to be placed should be placed in the sterile end of the room. These should be clean and dry. Each pack must be examined for holes in the wrapper, watermarks (indicative of area of moisture), expiry date and integrity of closure.

The tops of all furniture should be approximately the same height as the operating room table. This level is known as the level of sterility.

Unsterile equipment, furniture and personnel should remain twelve inches from any sterile surface. Unsterile personnel should never walk between two sterile fields.

Preparation of the patient

All patients can be a major source of contamination in the operating room. This can be minimized by preparing the surgical site (e.g. cutting eyelashes) and cleaning with a bacteriostatic agent, ensuring evacuation of the bladder and large intestine, transporting and the patient to the operating room in a clean gown and on a stretcher covered with clean linen.

Principles of Sterile Technique

- When bacteria cannot be eliminated from a field, they should be kept to an irreducible minimum.
- If there is any doubt about the sterility of anything, consider it to be unsterile.
- Persons who are sterile should touch only sterile articles while persons who are not sterile should touch only unsterile articles.
- Sterile persons should leaning over an unsterile area, while nonsterile persons should avoid reaching over a sterile field.
- Tables are sterile only at table level.
- Gowns are considered sterile only from waist to shoulder level in front, and upto the sleeves.
- The edge of anything that encloses sterile contents is not considered sterile.

- Sterile persons should keep well within the sterile area; nonsterile persons should keep away from the sterile area.
- Moisture is a potential source of contamination; so avoid using moisture soaked linen packages.
- Keep nonsterile personnel or visitors to a minimum.

Bad habits that die hard

- Preparing all trolleys required for a list before hand, long before they are needed.
- Unsterile person completing a trolley with chittle transfer forceps.
- Rushing through with scrubbing.
- Throwing around soiled linen and unsterile covers of disposable material such as gloves, syringes etc.
- Discarding swabs used for skin preparation onto the floor.
- Wearing a cap that does not fully cover the scalp hair and a mask that does not snugly cover the nose.
- Scrubbed sterile persons moving about with hands folded or with hands within the gown pockets.
- Letting a mask hang loose around the neck and reusing the same.
- Wearing the same footwear from an unrestricted area to a restricted area.

Sterilization

Previously sterilization was considered an absolute process by which all micro-organisms were destroyed. This is however impossible as micro-organisms die logarithmically. A practical definition implies reduction of micro-organism load to a level below that required to cause infection in most humans.

Several methods of sterilization are followed to ensure that the items being used are surgically safe. The most appropriate method is dependent however on the type of material, the inventory size, the use and the facilities available.

Sterilization using moist and dry heat are physical methods of sterilization. Moist heat is used as steam under pressure while dry heat is used as circulating hot air.

Sterilization methods of choice for articles during eye surgery:

1. Linen (gowns, caps, masks, drapes) : Autoclaving
2. Glassware (syringes): Dry heat sterilization
3. Metal instruments: Heat labile: Dry heat/ETO sterilization
Heat resistant: Autoclaving
4. Plastic instruments/components: Ethylene oxide sterilization.
5. Sharp edged instruments (e.g. Vannas scissors, keratome): ETO/Hot air oven/Chemical disinfection.
6. Intraocular lenses: Ethylene oxide sterilization.
7. Sutures (including monofilament nylon): Can be autoclaved.
8. Diathermy, cautery electrodes: Autoclaving
9. Endoilluminators/probes: Ethylene oxide sterilization
10. Lenses: Chemical disinfection
11. Silicone oil /buckles / sponges: Autoclaving

Autoclaving

This is a method of sterilization by moist heat that uses steam under pressure and is the most efficient, dependable and economical method of sterilization for items that are heat and moisture resistant.

The autoclave may have a “mains” steam supply or independent steam supply and could be of the gravity displacement or high pressure – high vacuum type.

Precautions to be taken to ensure proper sterilization are:

- Air from the chamber has to be thoroughly eliminated (by vacuum).

- Steam must be at recommended temperature and pressure, and for the recommended time period.
- Materials should be packed with good spacing so that steam reaches all parts of the load; preset trays are to be preferred.
- The chamber should not be opened prematurely.
- If dressings are wet or damaged when removed, consult engineer as the autoclave and not the methodology is faulty.
- Strictly apply sterility tests.
- To ensure absolute safety, it is advisable to increase the time by 50% of that recommended.

Hot air oven

This is a technique of dry heat sterilization that is recommended only for items liable to heat and moisture. Sterilization by heat that is dry requires higher temperatures because the catalyst, water is lacking. Unlike moist heat which kills micro-organisms by coagulation, dry heat kills by oxidation.

Dry heat has no corrosive effect on sharp edges or eroding effect on glass and so is well suited for cutting edge instruments, needles, and syringes. Powders, greases and anhydrous oils can be sterilized only by dry heat. Dry heat is destructive to linen, rubber and plastics.

The time and temperature necessary for sterilization depends to a large extent on the quantity of the item to be sterilized.

Precautions which should be taken while using a hot air oven are:

- It should not be overloaded.
- Glassware should be perfectly dry before placing in the oven.
- Rubber materials – except silicone rubber will not stand the temperature.
- For cutting instruments used in ophthalmic surgery, a sterilizing time of 2 hours at 150° C is recommended.

- To prevent cracking of glassware, the oven must be allowed to cool slowly for about two hours.

Boiling

Boiling is a method of heat disinfection. It however has no place in a modern hospital, not even under extremes of violation. If an autoclave is not available, an ordinary pressure cooker is an acceptable alternative.

Cold Sterilization

Radiation: Two methods are used, irradiation from a Cobalt 60 source or electron bombardment from a linear accelerator. The usual dose is 2.5 Mrad. Sterilization by radiation is successful for most disposable items that require sterilization only once.

Ethylene oxide (ETO) sterilization: At normal temperature and pressure, ethylene oxide is a penetrating gas with an ethereal smell. It is very inflammable and at concentrations above 3 percent, highly explosive. It is unsuitable for fumigating rooms because of this explosive property.

Ethylene oxide is effective against all micro-organisms including viruses and spores. It kills by alkylation and in addition reacts with RNA and DNA. The risk of toxicity thus exists.

The explosiveness of ethylene oxide is reduced by mixing with an inert gas like carbondioxide or by creating vacuum in the chamber before introducing ethylene oxide. If a leak occurs and it mixes with air, it forms a highly combustible mixture. Normally of 10-15% ethylene oxide with 85-90% CO₂ is used. Adequate humidity of 70-80% must be automatically provided by the sterilizer.

It can be used to sterilize a wide range of articles, but in particular, heat labile ones. Exposure is maintained for about an hour.

Since ethylene oxide residues are toxic, desorption of these must be ensured by either storing the goods on an open shelf for at least 24 hours or by using adequate post-vacuum, powerful filtered air rinse under vacuum and at

desired temperature. Apparatus sterilized by the ethylene oxide process should ideally not be used with saline or blood products before it has been flushed with sterile water. This precaution is essential because ethylene oxide residue can react with the chloride radical to form chlorohydrates, the toxicity of which is ill understood.

Cold sterilization using chemicals: Only disinfection is possible using chemical solutions. They should be used only when sterilization by heat is impracticable. All articles intended to be sterilized by this method should be free from debris, blood or pus.

Alcohols, aldehydes, phenol and coal tar derivatives, halogen compounds and synthetic detergents are the main classes of chemicals used for disinfection.

Of the alcohols, **ethyl alcohol** (60-70% concentration) and isopropyl alcohol are used mainly as skin disinfectants. They have no effect on viruses and spores.

Formaldehyde and activated glutaraldehyde (Cidex 2%) are the most frequently used aldehydes. Formaldehyde in aqueous solutions is markedly bactericidal, sporicidal and viricidal. In gaseous form, it is used for fumigation. Unless combined with sub-atmospheric steam, disinfection failures have been described in the past. The irritant and toxic vapour of formaldehyde can be nullified at completion of disinfection, by use of ammonia vapour.

Cidex is a buffered 2% solution of activated glutaraldehyde with 0.3% sodium bicarbonate (pH 7.5-8.5). It is a commercial preparation containing an anti-rust agent. Cidex kills vegetative bacteria and tubercle bacilli in 10-30 minutes and is sporicidal after 3-10 hours of holding. It is suitable for a variety of instruments but is of most importance for disinfection of lenses as it does not damage the cement or protective coating.

Cidex is only slightly irritant to the skin and mucosa but is highly irritant to the eye. Instruments disinfected using cidex should be

thoroughly rinsed in sterile water before use. Once activated, cidex is effective for 4 weeks. Disinfectant solutions should be date stamped and stock must be kept at a minimum. Bacterial contamination of dilute cidex solutions can occur if cork enclosures are used, or if the topping up of half empty bottles is practiced or stockbottles are refilled without reesterilization.

Carbolic acid (phenol in its pure state) is no longer being used because there are many derivatives that are more effective and less dangerous.

Dettol is chloroxylenol 4.8% and Terpineol 9%. It is used at 5% dilution. Minimum immersion time for ensuring disinfection is 10 minutes. It is relatively less effective against gram negative organisms. Dettol is slightly irritant and toxic in high concentrations.

Hibitane, a commonly used surgical disinfectant has chlorihexidine, a coal tar derivative. The hospital concentrate has 5% chlorhexidine. It is effective against gram positive and gram negative organisms though not against spores. Chlorhexidine is not compatible with soaps and should not be intentionally combined with these. For presurgical skin disinfection and emergency disinfection of heat labile instrument, 0.5% solution is used. For the latter, an immersion time of at least 10 minutes is a must. For presurgical rinse of hands, 0.5% concentration is used.

Hexachlorophene, another coal tar derivative has the advantage that it can be combined with soaps. It is also more effective against gram positive and gram negative organisms. Its effectively is cumulative and so repeated applications are essential. In combination with hibitane, it reduces scrub time to 3 minutes.

Cetavalon or Cetricimide is a quaternary ammonium synthetic detergent derivative. It is not compatible with soaps. Cetavalon is often combined with chlorhexidine to increase the antibacterial action. Savlon, the commercial preparation of cetavalon has 1.5% chlorhexidine gluconate and 15% cetricimide. For emergency disinfection, a 10% dilution of concentrate in 70%

methylated spirit is used. Immersion time for effective disinfection is 10 minutes. For presurgical rinsing of hands, it is used in 1% dilution.

Betadine or providone – iodine is a nonstinging, nonstaining water soluble iodine complex. It combines the lethal microbicidal effect of iodine without its irritant property. It kills all organisms including spores and has a more prolonged action than ordinary iodine. The action of betadine is unimpaired by blood, serum, pus or soap. An important precaution to be taken is to never use betadine detergent (which is used for the surgical scrub) for skin preparation (only an aqueous solution is to be used).

Caution during chemical sterilization

- Use only when sterilization by heat is impracticable.
- Articles should be free from debris, blood, and pus.
- Effectively can be increased by using twice the recommended concentration.
- Do not use alcohol to clean/disinfect equipment with lenses.
- Instruments soaked in activated glutaraldehyde (Cidex) will not be sterile unless they are soaked, totally submerged for ten hours.
- Chemical sterilization becomes ineffective in the presence of air bubbles within tubular instruments, failure to totally submerge the item and human error in glutaraldehyde solution preparation.
- Never use betadine detergent for skin preparation of the operating field.
- Do not intentionally combine hibitane (Chlorhexidine) with soaps, as they are incompatible.
- ETO is toxic, so gloves should be used when handling before aeration; employees should not stand in front of the door when opening the chamber.

Instrument Preparation

Ultrasonic processing

This is a method for effectively removing debris adherent to the instrument surface. Ultrasonic cleaning results from sound waves passing through water by a process of cavitation. It is emphasized that ultrasonic cleaning is not a substitute for decontamination described subsequently. If instruments are not decontaminated prior to being placed in the sonic washer, micro-organisms present on the instruments get deposited in the washer and create a source of cross contamination.

Terminal Decontamination

Instruments should be cleaned as soon as possible after use or exposure to avoid rapid multiplication of micro-organisms, drying of debris in serrations, and rusting or pitting of the metal.

Optimally, mechanical decontamination of the instruments with a washer – sterilizer should be undertaken. A washer sterilizer permits complete trays of instruments to be processed at one time. It provides sterile instruments for repackaging or storage or immediate reuse. It is suitable for unwrapped instruments only. The washing process is achieved by means of jet streams of air and steam that cause agitated turbulence in the detergent bath. A high temperature (270° F) steam sterilizing cycle follows this washing process.

If a washer – sterilizer is not available, instruments can be decontaminated as effectively by either of the following methods.

- a) Rinsing in a detergent germicide, placing the instruments in a perforated tray and autoclaving for 30 minutes at 270° F or 45 minutes at 250° F.
- b) Placing the instruments in a basin containing 2% trisodium phosphate and autoclaving for 30 minutes at 270° F or 45 minutes at 250° F.

Prior to decontamination, hand – scrubbing of instruments is undesirable because it causes

aerosol formation with the threat of disseminating micro-organisms into the air. Only in the event of an instrument that is in use dropping onto the floor should hand scrubbing be undertaken, keeping both instrument and brush beneath the water surface to prevent aerosolization.

All instruments must be inspected for cleanliness and proper functioning before placing in a tray or wrapper. All hinged instruments must be opened or unlocked to allow for steam contact on all surfaces. Instruments with several components, as also syringes, should be disassembled for sterilization. To prevent corrosion and stiffness, instruments must be periodically lubricated with oil in water emulsions. Unless the instrument is being sterilized by dry heat sterilization, it should never be lubricated with oil. The oil creates a film that is resistant to steam penetration.

Special silicone oils however allow steam penetration. Trays in which instruments are placed should have mesh bottoms with small openings. Instrument placement should be orderly and in a fixed fashion.

Drape packs should not be greater than 12 inches wide, 12 inches high and 20 inches long or weigh more than 12 pounds. A chemical indicator should be placed in the center of every pack. To allow steam or gas penetration, the packaging material should not be too thick.

Several factors control the safe storage time for sterile packed goods. The packaging material and its thickness, use of closed or open shelving, condition of storage area – cleanliness, temperature, humidity, use of dust covers and the number of times a package is handled prior to use after processing, all affect the safe storage time.

Sterilization monitoring systems

Monitoring the results of sterilization is essential to ensure safe sterile products during surgery. The main objective is to minimize infection potential. The methods used, the frequency of monitoring and interpretation of results must be standardized.

Steam Sterilization

Biological monitoring using spores of *Bacillus stercorophilus*, which is most resistant to moist heat, is the method of choice. However the time required to incubate and examine cultures makes it an impractical method for frequent use. Despite this, steam sterilizers should be impregnated on paper strips or in ampoules or in self contained plastic incubator tubes.

Most autoclaves have a mechanical control charting mechanism which indicates the time and temperature of the sterilizing cycle. The chart paper needs to be changed daily, dated and retained as a record. This chart may be the first indicator of a faulty sterilizing cycle.

Chemical thermal indicators are available as pressure sensitive tapes, or glass tubes with a pellet paper strips or cards. The paper strips should be incorporated in the centre of the pack to indicate that the steam has penetrated here. Some indicators have a sliding colour scale just like a clinical thermometer. In the high vacuum sterilizers, the Bowie - Dick test is used to test the adequacy of air removal during the prevacuum stage. It indicates if air pockets that will inhibit steam penetration are forming due to inadequate air removal.

Dry heat Sterilization

Spores of a nontoxigenic strain of *Clostridium tetani* are used as a microbiological indicator of dry heat efficiency. For routine use, a colour indicator tube (Brownie's) is also available. Thermocouples may also be used periodically.

Ethylene oxide (ETO) sterilization

Larger size ETO cabinets have a mechanical control chart as described under steam sterilization. The smaller ones usually do not have these charts.

Chemical thermal pressure sensitive colour indicators are used routinely. The indicator should be placed within every package processed with ETO. Biological monitoring of ETO sterilizers is done with an indicator containing *Bacillus subtilis*.

Monitoring of disinfectant efficacy

Testing of disinfectants can be undertaken using the Rideal - Walker test or Chick Martin test. Details of these tests are beyond the ambit of this text and may be found in any standard textbook of microbiology.

Availability of Vitreoretinal Surgeons with Vitrectomy Facilities in Rajasthan

Jaipur

1. Dr. Gopal Verma: Eye Surgery and Laser Centre, C-401, Malviya Nagar, Jaipur-17, Mob No. 09829052462
2. Dr. Pavan Shorey: Jaipur Hospital, Lal Kothi, Near S M S Stadium, Jaipur, Mob. No. 09414045217
3. Dr. Kamlesh Khilnani: Assoc. Prof, Department of Ophthalmology, S M S Medical College, Jaipur, Mob. No. 09414077341
4. Dr. Vinod Jain: Jain Eye Hospital, K-4/A, Fateh Tiba, Adarsh Nagar, Jaipur: Mob. No. 09414050027
5. Dr. Anil Verma: Anupam Hospital, 17, Dayal Nagar, Gopalpura Bypass, Jaipur. Mob. No. 09829212600
6. Dr. R K Sharma: Sahai Eye Hospital, Moti Doongri Road, Tilak Nagar, Jaipur. Mob. No. 09829054748
7. Dr. Sukesh Tandon: Tandon Eye Hospital, 5 Achrol House, Civil Lines, Jaipur, Mob. No. 09414079865
8. Dr. Vineet Pradhan: Retina Care Foundation, D-7, Dev Nagar, Opp. Community Centre, Tonk Road, Jaipur, Mob. No. 09829210724
9. Dr. Ajay Jhinja: C/o Dr. Virendra Agarwal Laser Centre, Shyam Anukampa Towers 2, Ashok Marg, C-Scheme, Jaipur, Mob. No. 09314481058

Jodhpur

1. Dr. Ratan Purohit: S J Eye Hospital, & Ram Rishi Laser Centre, 562, 7th C Road, Near Satsang Bhawan, Sardarpura, Jodhpur, Mob. No. 09314700878
2. Dr. Sanjeev Desai: E-22, Shastri Nagar, Jodhpur, Phone No. 2771714

Udaipur

1. Dr. Nirbhay Verma: Nirbhay Eye Hospital, 1-C, Madhuban, Udaipur, Phone No. 2490121

Ajmer

1. Dr. Arun Kshetrapal: Kshetrapal Eye Hospital & Research Centre, Kutchery Road, Ajmer, Mob. No. 09414002848

Sri Ganganagar

1. Dr. Rajesh Chalana: Nayan Mandir, 3/24, Housing Board, Sri Ganganagar, Mob. No. 09414953200

Kota

1. Dr. Vineeta Garg: Om Hospital, 1-A-12, S F S, Talwandi, Kota, Mob. No. 09828571422